

International Guidelines for the Diagnosis and Management of Hereditary Hemorrhagic Telangiectasia

M.E. Faughnan MD MSc^{1,2}, V.A. Palda MD MSc³, G. Garcia-Tsao MD⁴, U.W. Geithoff MD PhD^{5,6}, J. McDonald MS CGC⁷, D.D. Proctor MD⁸, J. Spears MD MPH⁹, D.H. Brown MD¹⁰, E. Buscarini MD¹¹, M.S. Chesnutt MD¹², V. Cottin MD PhD¹³, A. Ganguly PhD¹⁴, J.R. Gossage MD¹⁵, A.E. Guttmacher MD¹⁶, R.H. Hyland MD¹, S.J. Kennedy MS CGC¹⁷, J. Korzenik MD¹⁸, J.J. Mager MD PhD¹⁹, A.P. Ozanne MD²⁰, J.F. Piccirillo MD²¹, D. Picus MD²², H. Plauchu MD PhD²³, M.E.M. Porteous MD²⁴, R.E. Pyeritz MD PhD²⁵, D.A. Ross MD²⁶, C. Sabba MD²⁷, K. Swanson DO²⁸, P. Terry MD²⁹, M.C. Wallace MD³⁰, C.J.J. Westermann MD PhD¹⁹, R.I. White MD³¹, L.H. Young MD³² and R. Zarrabeitia MD³³.

¹Division of Respiriology, Department of Medicine, St. Michael's Hospital, University of Toronto, Toronto, ON, Canada

²Li Ka Shing Knowledge Institute, St. Michael's Hospital, University of Toronto, Toronto, ON, Canada

³Departments of Medicine, Health Policy, Management and Evaluation, University of Toronto, Toronto, ON, Canada

⁴Section of Digestive Diseases, Department of Internal Medicine, Yale University School of Medicine, New Haven, CT, USA

⁵University of the Saarland, Medical Faculty, Homburg/Saar, Germany

⁶Department of Otorhinolaryngology, Holweide Hospital, Hospitals of the City of Cologne, Cologne, Germany

⁷Department of Radiology, University of Utah, Salt lake City, Utah.

⁸Section of Digestive Diseases, Yale University School of Medicine, New Haven, CT, USA

⁹Department of Surgery, St. Michael's Hospital, University of Toronto, Toronto, Ontario, Canada

¹⁰Dept of Otolaryngology/Head & Neck Surgery, University of Toronto, Toronto, ON, Canada

¹¹U.O di Gastroenterologia ed Endoscopia Digestiva, Ospedale Maggiore, Crema, Italy

¹²Portland VA Medical Center, HHT Center of Excellence, Dotter Interventional Institute, Oregon Health & Science University

¹³University of Lyon, Hospices Civils de Lyon, National reference center for rare pulmonary diseases, Lyon, France

¹⁴Department of Genetics, University of Pennsylvania School of Medicine, Philadelphia, PA, USA

¹⁵Medical College of Georgia, Augusta, GA, USA

¹⁶National Human Genome Research Institute, NIH, Bethesda, MD

¹⁷Ontario Newborn Screening Program and Regional Genetics Program, Children's Hospital of Eastern Ontario, Ottawa, ON, Canada

¹⁸Massachusetts General Hospital Gastrointestinal Unit, Boston, MA, USA

¹⁹St. Antonius Hospital, Nieuwegein, the Netherlands

²⁰Interventional Neuroradiology, Hopital de Bicetre, Paris, France

²¹Department of Otolaryngology-Head & Neck Surgery, Washington University School of Medicine, St. Louis, MO, USA

²²Department of Radiology, Washington University School of Medicine. St Louis, MO, USA

²³National Reference Center for HHT Disease, Hotel Dieu Hospital, Hospices Civils de Lyon, Lyon, France

²⁴SE Scotland Genetic Service, Western General Hospital, Edinburgh, Scotland

²⁵University of Pennsylvania School of Medicine, Philadelphia, PA, USA

²⁶Department of Surgery, St. Vincent's Medical Center, Bridgeport, CT, USA

²⁷Department of Internal Medicine and Public Health, University of Bari, Bari, Italy

²⁸Mayo Clinic Division of Pulmonary & Critical Care Medicine, Rochester, MN, USA

²⁹Division of Pulmonary & Critical Care Medicine, Johns Hopkins University, Baltimore, MD, USA

³⁰Division of Neurosurgery, Krembil Neuroscience Centre, University Health Network, Toronto, ON, Canada

³¹Yale Vascular Malformation Center, Yale University School of Medicine, New Haven, CT, USA

³²Section of Cardiovascular Medicine, Yale University School of Medicine, New Haven, CT, USA

³³Servicio de Medicina Interna, Unidad HHT, Hospital Sierrallana (Servicio Cántabro de Salud), Torrelavega (Cantabria), Spain

Word count=5536

Key Words:

Guidelines

Hereditary hemorrhagic telangiectasia

Arteriovenous malformation

Telangiectasia

Epistaxis

Abstract

HHT is an autosomal dominant disease with an estimated prevalence of at least 1/5000 which can frequently be complicated by the presence of clinically significant arteriovenous malformations in the brain, lung, gastrointestinal tract and liver. HHT is under-diagnosed and families may be unaware of the available screening and treatment, leading to unnecessary stroke and life-threatening hemorrhage in children and adults. The goal of this international HHT guidelines process was to develop evidence-informed consensus guidelines regarding the diagnosis of HHT and the prevention of HHT-related complications and treatment of symptomatic disease. The overall guidelines process was developed using the AGREE framework, using a systematic search strategy and literature retrieval with incorporation of expert evidence in a structured consensus process where published literature was lacking. The Guidelines Working Group included experts (clinical and genetic) from eleven countries, in all aspects of HHT, guidelines methodologists, health care workers, health care administrators, HHT clinic staff, medical trainees, patient advocacy representatives and patients with HHT. The Working Group determined clinically relevant questions during the pre-conference process. The literature search was conducted using the OVID MEDLINE database, from 1966 to October 2006. The Working Group subsequently convened at the Guidelines Conference to partake in a structured consensus process using the evidence tables generated from the systematic searches. The outcome of the conference was the generation of 33 recommendations for the diagnosis and management of HHT, with at least 80% agreement amongst the expert panel for 30 of the 33 recommendations.

Introduction

HHT is an autosomal dominant disease with an estimated prevalence of 1/5000[1] and is thought to be present in all races and parts of the world. Though epistaxis is the most common symptom of HHT and mucocutaneous telangiectasia the most common sign[2], HHT is also frequently complicated by the presence of arteriovenous malformations (AVMs) in the brain, lung, gastrointestinal (GI) tract and liver.

Unfortunately, HHT is often not diagnosed and entire families therefore remain unaware of available screening and treatment, and children and adults unnecessarily develop stroke or life-threatening hemorrhage. The goal of the international HHT guidelines process was to develop evidence-based consensus guidelines for the diagnosis of HHT, the prevention of HHT-related complications and treatment of symptomatic disease.

Methods

The overall guidelines process (Figure) was developed using the AGREE framework [3] with guidelines methodologists. The structure was that of a systematic evidence-based process with incorporation of expert evidence in a structured consensus process where evidence was lacking. We expected only weak or poor evidence in most areas, but chose this approach to maximize quality and applicability of the guidelines and provide a foundation for future research and guidelines in HHT.

Determination of Need for Guidelines

The need for clinical guidelines for HHT was identified by the HHT Foundation International, an international advocacy group for people with HHT, and the Foundation's Scientific and Medical Advisory Board. This was based on their consistent observations of care gaps in HHT, specifically that HHT is under-diagnosed, that there are frequent delays in diagnosis and that most patients and families with HHT are not receiving appropriate preventative treatment. No clinical guidelines were in place for the multi-system manifestations of the disorder, with the exception of the recently published guidelines for liver vascular malformations (VMs)[4].

Membership of the HHT Guidelines Working Group

An organizing committee of clinicians, scientists, methodologists, patients and Foundation members selected the members of the HHT Guidelines Working Group. This included experts (clinical and genetic) from eleven countries, in all aspects of HHT, guidelines methodologists, health care workers and administrators, HHT Foundation representatives and patients with HHT. Each member was also a member of a topic subgroups [diagnosis, epistaxis, cerebral vascular malformations (CVMs), pulmonary AVMs (PAVMs), GI bleeding and liver VMs]. Patients contributed to the development of the clinically relevant questions and the recommendations, with particular input regarding values around recommendations.

Determination of Clinically Relevant Questions

During the pre-conference process, the topic subgroups worked by email to develop clinically relevant questions. The subgroups circulated and edited these through several iterations. These formed the basis for the literature review.

Background Preparation

A literature search was conducted using the OVID MEDLINE database from 1966 to October 2006 to identify relevant English-language publications, using the search strategies as outlined in Appendix I. Hand searches of relevant articles and reviews were also done for each clinically relevant question. Bibliographies of retrieved publications were reviewed to identify sources not obtained in our search. Publications in abstract form were included to minimize publication bias. One author (MEF) and the literature review assistant (J. Silver) independently reviewed abstracts and any relevant studies were pulled for review. Inclusion and exclusion criteria for study selection are listed in Appendix I. Results from selected studies were extracted into evidence tables, and along with original papers, were sent to participants for review, and to determine if any relevant literature was missing.

Determination of Clinical Recommendations

Participants convened at the Guidelines Conference to partake in a structured consensus process using the evidence tables. With the assistance of professional guidelines facilitators, topic subgroups prioritized clinically relevant questions and then generated recommendations for these. All participants assembled together afterwards to vote for all generated recommendations. Those recommendations achieving less than 80% agreement were further discussed, revised again with a facilitator, and re-voted. Wording of recommendations was considered final and are presented with the % agreement obtained on the final vote. Priorities for future research were also identified during the process (Appendix II).

Grading of evidence

Each recommendation was graded to indicate the level of evidence available using the classification system of the Canadian Task Force on the Periodic Health Examination [5] (Table 1). In addition, values around recommendations were generated using the GRADE instrument [6, 7] and these were reported as “strength of the recommendation”. The “strength of the recommendation” incorporated evidentiary and non-evidentiary factors, including baseline risks of outcomes, benefits of treatment, potential harms of treatment, certainty of point estimates, levels of evidence. Values were also incorporated, such as the importance of certain outcomes to stakeholders and other factors such as availability of certain tests, for example.

General Organization

The pre-conference process occurred by email over six months leading up to the two-day Guidelines Conference near Toronto, Canada, in November 2006. The Conference was held in a facility with anonymous key pad voting technology. The large group sessions were recorded (audio) and minuted.

Preparation of Report

Topic leaders generated each area of the manuscript, which was then revised by MEF, VP and the topic members for each group, and then reviewed by the other authors. The literature search referenced was that obtained in October 2006. At the time of final manuscript review, two steps were taken to assure that no generated recommendation needed immediate revision. First, a literature search for any interim Randomized Controlled Trials in HHT was performed, which revealed none. Secondly, the Working Group was polled for knowledge of any recent publications that would lead to a significant change in any of the recommendations and none were identified.

Role of Funding Sources

Although the funding organizations were not directly involved in the generation of the recommendations, some of the participants in the guidelines process were also board members of the HHT Foundation International and its Scientific and Medical Advisory Board. The other funding sources had no role in the design, conduct and reporting of the study or in the decision to submit the results for publication.

References

1. Kjeldsen AD, Vase P, Green A. Hereditary haemorrhagic telangiectasia: a population-based study of prevalence and mortality in Danish patients. *J Intern Med* 1999; 245(1): 31-39.
2. Plauchu H, de Chadarevian JP, Bideau A, Robert JM. Age-related clinical profile of hereditary hemorrhagic telangiectasia in an epidemiologically recruited population. *Am J Med Genet* 1989; 32(3): 291-297.
3. Collaboration TA. Appraisal of Guidelines for Research & Evaluation (AGREE) Instrument. www.agreecollaboration.org 2001.
4. Buscarini E, Plauchu H, Garcia Tsao G, White RI, Jr., Sabba C, Miller F, Saurin JC, Pelage JP, Lesca G, Marion MJ, Perna A, Faughnan ME. Liver involvement in hereditary hemorrhagic telangiectasia: consensus recommendations. *Liver Int* 2006; 26(9): 1040-1046.
5. Goldbloom R, Battista RN. The periodic health examination: 1. Introduction. *CMAJ* 1986; 134(7): 721-723.
6. Schunemann HJ, Jaeschke R, Cook DJ, Bria WF, El-Solh AA, Ernst A, Fahy BF, Gould MK, Horan KL, Krishnan JA, Manthous CA, Maurer JR, McNicholas WT, Oxman AD, Rubenfeld G, Turino GM, Guyatt G. An official ATS statement: grading the quality of evidence and strength of recommendations in ATS guidelines and recommendations. *Am J Respir Crit Care Med* 2006; 174(5): 605-614.
7. Atkins DL, Kenney MA. Automated external defibrillators: safety and efficacy in children and adolescents. *Pediatr Clin North Am* 2004; 51(5): 1443-1462.

Abbreviations:

ACVRL1= activin A receptor type II-like 1 gene
AgNO₃=silver nitrate
APC= argon plasma coagulation
AV=arteriovenous
AVF=arteriovenous fistula
AVMs=arteriovenous malformations
BIL=biliary
CAVM=cerebral arteriovenous malformations
CO₂=carbon dioxide
CT=computed tomography
CVMs=cerebral vascular malformations
DVA=developmental venous anomaly
EGD= esophagogastroduodenoscopy
ENG=endoglin
ENT=ear nose and throat
GI=gastrointestinal
HA=hepatic artery
HF=heart failure
HHT= hereditary hemorrhagic telangiectasia
HHT1= hereditary hemorrhagic telangiectasia type 1
HHT2= hereditary hemorrhagic telangiectasia type 2
IV=intravenous
MR=magnetic resonance
MRI=magnetic resonance imaging
PaO₂= arterial partial pressure of oxygen
PAVMs=pulmonary arteriovenous malformations
PHT=portal hypertension
PV=portoavenous
TCD=transcranial Doppler
TTCE=transthoracic contrast echocardiography
VMs=vascular malformations

Diagnosis of HHT

Background

Making the diagnosis of HHT in a patient allows for the appropriate screening and preventative treatment to be undertaken in the patient and their affected family members. HHT has traditionally been diagnosed on the basis of its clinical features but can now also be diagnosed using genetic testing. We reviewed the evidence and expert experience for clinical and genetic diagnosis in HHT.

The clinical diagnostic features of HHT have been identified by describing the clinical presentation of individuals who have known or suspected HHT and their close relatives. The average age of onset for epistaxis is 12 years, with nearly 100% affected by age 40 years [1-4]. Most patients report the appearance of telangiectasia of the mouth, face or hands 5-30 years after the onset of nosebleeds; most commonly during the third decade. Unfortunately, there are no longitudinal natural history studies of HHT clinical manifestations and how these might vary with genotype.

In 2000, consensus clinical diagnostic criteria known as the Curaçao Criteria were published[5] (see Table 2). Using these criteria, a diagnosis of HHT is considered “definite” if 3 or more criteria are present, “possible or suspected” if 2 criteria are present, and “unlikely” if 0 or 1 criterion is present.

There have been no studies reporting sensitivity and specificity of the Curaçao Criteria, but the expert panel agreed that the Curaçao Criteria are particularly helpful in two situations: discriminating affected from non-affected older adults and ruling-in the diagnosis in younger adults and children. The expert panel was specifically concerned about the risk of missing diagnoses in children and young adults, who might have no epistaxis or visible telangiectases, yet have undiagnosed PAVMs or CVMs [6]. It is in these groups that genetic testing should be most useful.

The goal of genetic testing for HHT is to clarify the specific HHT mutation in an HHT family, allowing diagnosis among those relatives (often children and young adults) who do not meet clinical diagnostic criteria. Genetic testing is performed first on the index case in the family and involves DNA sequencing and deletion/duplication analysis of the coding exons of the endoglin gene (*ENG*, HHT1) and the activin A receptor type II-like 1 gene (*ACVRL1*, HHT2). Mutations in these genes account for the majority of cases of HHT. At least two other HHT loci have been described, though specific genes at these loci are not yet identified [7, 8]. Mutations in the *SMAD4* gene can cause a rare syndrome which combines juvenile polyposis and HHT [9]. Genetic testing in HHT is complex relative to many other genetic conditions since a mutation in one of multiple genes can cause the condition, not all genes that can cause HHT have been discovered, and there are no “common mutations”, with most families having their own “private” HHT mutation.

Several authors have reported [10, 11] a clinical sensitivity/mutation detection rate of approximately 75% for sequence analysis of *ENG* and *ACVRL1*. Use of an additional method to detect large deletion/duplication mutations increases the detection rate by approximately 10% [10, 11]. Recent reports suggest that about 1-3% of patients clinically diagnosed with HHT will have a mutation detected in the *SMAD4* gene, or about 10% of those who test negative for *ENG* and *ACVRL1* mutations [11-13].

There is considerable clinical overlap between patients/families with *ENG* mutation and those with *ACVRL1* mutation, with VMs reported in similar organs in both types [14-16]. The expert panel agreed that *ENG* versus *ACVRL1* genotype should not significantly influence screening recommendations for VMs. Most HHT patients/families with *SMAD4* mutation reported to date have juvenile polyposis and are therefore are at risk of GI malignancy [9, 12].

There is currently no evidence about impact of prenatal testing for HHT and no consensus among experts about how fetal diagnosis might alter pregnancy or delivery management. Expert experience is that prenatal diagnosis is not commonly sought in HHT, and is most often requested as an alternative to postnatal diagnostic testing when there is already another reason for performing prenatal testing.

Recommendations

<p>The expert panel recommends that clinicians diagnose HHT using the Curaçao Criteria (see Table) or by identification of a causative mutation.</p> <p>Clinical Considerations: Applying the Curaçao Criteria for clinical diagnosis of HHT requires a targeted, multi-generation family history for HHT, given that most individuals with HHT will have an affected parent, grandparent and other close relatives. When applying the Curaçao Criteria, the clinician should consider the patient's age, given the frequently delayed appearance of the signs and symptoms of HHT. At least 90% of patients with HHT meet the clinical criteria by age 40, but few do in the first decade of life. If a patient has clinical features suggestive of HHT, but no family history, it is possible that patient has a new mutation and therefore the diagnosis of HHT remains possible.</p>	<p>Level of evidence: III</p> <p>Strength of recommendation: Weak</p> <p>Agreement: 82%</p>
<p>The expert panel recommends that clinicians consider the diagnosis of HHT in patients with one or more Curaçao criteria (see Table).</p> <p>Clinical Considerations: When applying the Curaçao Criteria for clinical diagnosis, identifying 2 or less of the criteria after clinical examination and history should not be</p>	<p>Level of evidence: III</p> <p>Strength of recommendation: Weak</p> <p>Agreement: 91%</p>

<p>considered sufficient evidence to rule out the diagnosis, particularly in the first few decades of life.</p>	
<p>The expert panel recommends that asymptomatic children of a parent with HHT be considered to have possible HHT, unless excluded by genetic testing.</p> <p>Clinical Considerations: Given the expected poor sensitivity of the Curaçao Criteria for clinical diagnosis in children, the clinician can clarify the diagnosis using genetic testing, if a familial mutation has been identified. If genetic testing is not possible, the clinician should proceed as if the child has HHT and consider appropriate screening for visceral AVMs.</p>	<p>Level of evidence: III</p> <p>Strength of recommendation: Weak</p> <p>Agreement: 87%</p>
<p>The expert panel recommends that clinicians refer patients for diagnostic genetic testing for HHT</p> <ol style="list-style-type: none"> 1. To identify the causative mutation in a family with clinically confirmed HHT 2. To establish a diagnosis in relatives of a person with a known causative mutation, including: <ol style="list-style-type: none"> a. Individuals who are asymptomatic or minimally symptomatic b. Individuals who desire prenatal testing 3. To assist in establishing a diagnosis of HHT in individuals who do not meet clinical diagnostic criteria <p>Clinical Considerations: Genetic testing for HHT is a multi-step process. In an experienced lab, the index case is generally tested by sequence and deletions/duplications analysis of both the <i>ENG</i> and <i>ACVRL1</i> genes. It is reasonable to perform the deletion/duplication analysis either simultaneously with the sequence analysis or only in cases in which the sequence analysis is negative or equivocal.</p> <p>If an HHT causing mutation is identified in the index case (test is positive), diagnostic genetic testing for HHT can be offered to all at risk relatives. These relatives would have “family specific” mutation testing by targeted sequencing.</p> <p>If no mutation is identified (test is negative) in the index case, diagnostic genetic testing can not be offered to other family members. Such families should be advised that, in the future, currently undetectable HHT mutations will become detectable as new genes and testing methods are discovered. In the meantime, diagnosis and medical management of at risk family members will rely on clinical findings and knowledge of the natural history of HHT.</p>	<p>Level of evidence: III</p> <p>Strength of recommendation: Weak</p> <p>Agreement: 80%</p>

<p>If a genetic variant of uncertain significance is identified (test is equivocal) in the index case, additional confirmatory testing may be available, or additional interpretive information may become available in the future, to clarify whether the genetic variant in question is in fact a benign variant or a disease causing mutation.</p>	
<p>The expert panel recommends that for individuals who test negative for <i>ENG</i> and <i>ACVRL1</i> coding sequence mutations, <i>SMAD4</i> testing should be considered to identify the causative mutation.</p> <p>Clinical Considerations: If full gene analysis for the <i>ENG</i> and <i>ACVRL1</i> genes is negative, the next step is for the clinician to request similar testing of the <i>SMAD4</i> gene.</p>	<p>Level of evidence: III</p> <p>Strength of recommendation: Weak</p> <p>Agreement: 93%</p>
<p>The expert panel recommends that all HHT patients and their families with <i>SMAD4</i> gene mutations should undergo gastrointestinal screening for polyposis and gastrointestinal malignancies as per national screening recommendations.</p> <p>Clinical Considerations: Appropriate screening for patients and with the <i>SMAD4</i> gene mutations includes colonic screening for polyposis with colonoscopy, starting at age 15-18 and every one to two years thereafter. The first colonoscopy should be performed at an age five years younger than that at which the youngest family member developed colon cancer. Affected patients should also undergo upper GI surveillance with esophagogastroduodenoscopy (EGD)/enteroscopy/small bowel series or capsule study starting at age 25 and every one to two years thereafter in accordance with previously published guidelines[17].</p>	<p>Level of evidence: III</p> <p>Strength of recommendation: Strong</p> <p>Agreement: 97%</p>

References

1. Plauchu H, de Chadarevian JP, Bideau A, Robert JM. Age-related clinical profile of hereditary hemorrhagic telangiectasia in an epidemiologically recruited population. *Am J Med Genet* 1989; 32(3): 291-297.
2. Porteous ME, Burn J, Proctor SJ. Hereditary haemorrhagic telangiectasia: a clinical analysis. *J Med Genet* 1992; 29(8): 527-530.
3. Berg J, Porteous M, Reinhardt D, Gallione C, Holloway S, Umasunthar T, Lux A, McKinnon W, Marchuk D, Gutmacher A. Hereditary haemorrhagic telangiectasia: a questionnaire based study to delineate the different phenotypes caused by endoglin and *ALK1* mutations. *J Med Genet* 2003; 40(8): 585-590.

4. OS AA, Friedman CM, White RI, Jr. The natural history of epistaxis in hereditary hemorrhagic telangiectasia. *Laryngoscope* 1991; 101(9): 977-980.
5. Shovlin CL, Guttmacher AE, Buscarini E, Faughnan ME, Hyland RH, Westermann CJ, Kjeldsen AD, Plauchu H. Diagnostic criteria for hereditary hemorrhagic telangiectasia (Rendu-Osler-Weber syndrome). *Am J Med Genet* 2000; 91(1): 66-67.
6. Morgan T, McDonald J, Anderson C, Ismail M, Miller F, Mao R, Madan A, Barnes P, Hudgins L, Manning M. Intracranial hemorrhage in infants and children with hereditary hemorrhagic telangiectasia (Osler-Weber-Rendu syndrome). *Pediatrics* 2002; 109(1): E12.
7. Cole SG, Begbie ME, Wallace GM, Shovlin CL. A new locus for hereditary haemorrhagic telangiectasia (HHT3) maps to chromosome 5. *J Med Genet* 2005; 42(7): 577-582.
8. Bayrak-Toydemir P, McDonald J, Akarsu N, Toydemir RM, Calderon F, Tuncali T, Tang W, Miller F, Mao R. A fourth locus for hereditary hemorrhagic telangiectasia maps to chromosome 7. *Am J Med Genet A* 2006; 140(20): 2155-2162.
9. Gallione CJ, Repetto GM, Legius E, Rustgi AK, Schelley SL, Tejpar S, Mitchell G, Drouin E, Westermann CJ, Marchuk DA. A combined syndrome of juvenile polyposis and hereditary haemorrhagic telangiectasia associated with mutations in *MADH4* (*SMAD4*). *Lancet* 2004; 363(9412): 852-859.
10. Bossler AD, Richards J, George C, Godmilow L, Ganguly A. Novel mutations in *ENG* and *ACVRL1* identified in a series of 200 individuals undergoing clinical genetic testing for hereditary hemorrhagic telangiectasia (HHT): correlation of genotype with phenotype. *Hum Mutat* 2006; 27(7): 667-675.
11. Prigoda NL, Savas S, Abdalla SA, Piovesan B, Rushlow D, Vandezande K, Zhang E, Ozelik H, Gallie BL, Letarte M. Hereditary haemorrhagic telangiectasia: mutation detection, test sensitivity and novel mutations. *J Med Genet* 2006; 43(9): 722-728.
12. Gallione CJ, Richards JA, Letteboer TG, Rushlow D, Prigoda NL, Leedom TP, Ganguly A, Castells A, Ploos van Amstel JK, Westermann CJ, Pyeritz RE, Marchuk DA. *SMAD4* mutations found in unselected HHT patients. *J Med Genet* 2006; 43(10): 793-797.
13. Lesca G, Burnichon N, Raux G, Tosi M, Pinson S, Marion MJ, Babin E, Gilbert-Dussardier B, Riviere S, Goizet C, Faivre L, Plauchu H, Frebourg T, Calender A, Giraud S. Distribution of *ENG* and *ACVRL1* (*ALK1*) mutations in French HHT patients. *Hum Mutat* 2006; 27(6): 598.
14. Kjeldsen AD, Moller TR, Brusgaard K, Vase P, Andersen PE. Clinical symptoms according to genotype amongst patients with hereditary haemorrhagic telangiectasia. *J Intern Med* 2005; 258(4): 349-355.
15. Letteboer TG, Mager JJ, Snijder RJ, Koeleman BP, Lindhout D, Ploos van Amstel JK, Westermann CJ. Genotype-phenotype relationship in hereditary haemorrhagic telangiectasia. *J Med Genet* 2006; 43(4): 371-377.
16. Bayrak-Toydemir P, McDonald J, Markewitz B, Lewin S, Miller F, Chou LS, Gedge F, Tang W, Coon H, Mao R. Genotype-phenotype correlation in hereditary hemorrhagic telangiectasia: mutations and manifestations. *Am J Med Genet A* 2006; 140(5): 463-470.

17. Dunlop MG. Guidance on gastrointestinal surveillance for hereditary non-polyposis colorectal cancer, familial adenomatous polyposis, juvenile polyposis, and Peutz-Jeghers syndrome. *Gut* 2002; 51 Suppl 5: V21-27.

Epistaxis

Background:

Recurrent spontaneous epistaxis is the most common symptom of HHT and often leads to iron-deficiency anemia[1]. Epistaxis appears before the age of 20 years in about 50 % of patients, with 78 – 96 % of all HHT patients developing it eventually[2]. During the guidelines development process, patients identified epistaxis as a priority HHT-related health concern affecting their everyday life and the literature suggests that epistaxis is an important factor reducing quality of life in HHT [3]. We reviewed the evidence for treatment of HHT-related epistaxis, searching for studies regarding treatment of the usual chronic recurrent epistaxis as well as of acute episodes of epistaxis requiring urgent medical consultation.

Non-invasive management of chronic recurrent epistaxis in HHT has focused to date on prevention of epistaxis events through measures to maintain integrity of the nasal mucosa, such as humidification. The rationale for humidification is that endonasal crusting and airflow lead to damage of endonasal telangiectasia and secondary bleeding whereas humidification should help prevent endonasal crusting. There are small case series of various topical medications, including lubricants (saline, antibiotic ointments, etc.)[4, 5], as well as topical estrogen cream/ointment[6] and antifibrinolytics[7], with variable success in decreasing HHT-related epistaxis. There is insufficient published data to recommend one topical therapy over another, however expert experience is that there is mild benefit from humidification and that the risk of topical lubricants and saline is very low.

Procedural therapies for chronic HHT-related epistaxis include endonasal laser, electrical or chemical coagulation techniques, replacement of the fragile endonasal mucosa by skin or buccal mucosa (dermoplasty), nasal artery embolization and closure of the nasal cavity (known as Young's procedure). There have been no controlled or well designed comparative studies of any of these procedures in HHT-related epistaxis, for either acute or chronic management. Case series and expert opinion of endonasal coagulation for treatment of moderate HHT-related epistaxis suggests that most types of endonasal coagulation appear to be low-risk procedures with subjective improvement in most patients [1, 4, 8-12]. Chemical cautery (e.g. AgNO₃) and CO₂-laser-coagulation appear to have poorer outcomes in HHT and higher risk of intraoperative bleeding[4]. Septal dermoplasty has been reported, in one uncontrolled retrospective case series of patients with severe epistaxis, to decrease mean transfusion requirements and to improve subjective quality of life, but follow-up was available in <50% of treated patients[13] and complications included endonasal crusting and dryness. Young's procedure has been shown in a few small case series of patients with severe epistaxis to cause cessation of epistaxis and also to improve in quality of life, though patients report side effects of chronic mouthbreathing[14-16]. Nasal artery embolization is generally not useful for treatment of chronic epistaxis, since the effect is generally short-term [17, 18]. Submucosal or intravascular endonasal injections of different substances have been reported[19, 20], often with reduction in epistaxis but also reports of complications such as severe allergic reactions and blindness[20].

The expert panel agreed that given the learning curve for surgical management of chronic HHT-related epistaxis, involvement of surgeons with expertise in HHT-related epistaxis may increase the likelihood of appropriate choice of treatment and improve outcomes of therapy. The expert panel also agreed that this applied to nasal surgery for indications other than epistaxis, in HHT patients.

Several medical therapies have been reported for HHT-related epistaxis, but there are no well designed studies supporting their effectiveness and most studies have been limited by the lack of a validated sensitive outcome measure. There is one negative randomized placebo-controlled double-blind trial of estrogen [21], and another of tranexamic acid [22], in which investigators were unable to demonstrate significant improvement in hemoglobin (primary outcome) but did demonstrate significant improvement in subjective epistaxis (secondary outcome)[22].

There are no well designed studies of the first-line management of acute epistaxis, though nasal packing is frequently used to control acute bleeding. However, endonasal telangiectasia are extremely fragile and therefore packing removal can cause re-bleeding. This can be minimized with atraumatic packing, for example using lubricated or pneumatic packing, the latter allowing insertion and removal of the packing in a deflated size. Low pressure pneumatic packing may also minimize mucosal ischemic damage. Two uncontrolled case series of embolization[18, 23], in patients with severe ongoing epistaxis despite packing, reported excellent immediate success rates (80-100%), but with early recurrence of epistaxis and risk of serious procedural complications (stroke, tissue necrosis).

The panel also discussed management when an HHT patient has an indication for antiplatelet or anticoagulant therapy. There are no published studies regarding the use of anticoagulants in HHT, but expert experience revealed a wide range of outcomes, with some HHT patients tolerating anticoagulation and others developing life-threatening bleeding.

Recommendations

<p>The expert panel recommends that physicians advise patients with HHT-related epistaxis to use agents that humidify the nasal mucosa to prevent epistaxis.</p>	<p>Level of evidence: III</p> <p>Strength of recommendation: Weak</p> <p>Agreement: 94%</p>
<p>The expert panel recommends that for HHT-related epistaxis requiring surgical intervention, clinicians consider endonasal coagulation as a first line treatment option.</p> <p>Clinical Considerations: Endonasal coagulation should be</p>	<p>Level of evidence: III</p> <p>Strength of recommendation: Weak</p> <p>Agreement: 93%</p>

<p>applied carefully and with experience to avoid complications like septal perforation (which often leads to worse epistaxis), even if it means repeating the intervention several times. If recurrent endonasal coagulation has not been effective and epistaxis is severe, then more invasive procedures, such as septal dermoplasty or Young's procedure, can be considered.</p>	
<p>The expert panel recommends that clinicians refer HHT patients with epistaxis and who desire treatment to otorhinolaryngologists with HHT expertise for evaluation and treatment.</p> <p>Clinical considerations: Primary physicians are key players in the care of HHT patients, especially in the emergency situation. In the patient with epistaxis problematic enough to warrant consideration of treatment, consultation with an otorhinolaryngologist with HHT expertise should help guide the intervention choice, to maximize effectiveness and reduce risk, in this life-long rare disorder.</p>	<p>Level of evidence: III</p> <p>Strength of recommendation: Weak</p> <p>Agreement: 87%</p>
<p>The expert panel recommends that when considering nasal surgery for reasons other than epistaxis, the patient and clinician obtain consultation from an otorhinolaryngologist with expertise in HHT-related epistaxis.</p> <p>Clinical Considerations: In the patient with HHT and an unrelated ENT problem requiring surgery, consultation with an otorhinolaryngologist with HHT expertise should help guide the procedural interventions to minimize risk of worsening epistaxis.</p>	<p>Level of evidence: III</p> <p>Strength of recommendation: Weak</p> <p>Agreement: 100%</p>
<p>The expert panel recommends that the treatment for acute epistaxis requiring intervention include packing with material or products that have a low likelihood of causing re-bleeding with removal (e.g., lubricated low-pressure pneumatic packing).</p> <p>Clinical considerations: In order to perform atraumatic packing, the clinician can lubricate the packing or use a pneumatic packing which allows insertion and removal of the packing in a deflated size. When using pneumatic packing, a low pressure packing would be preferable. This recommendation is specifically addressing nasal packing performed by physicians, though the expert panel is aware that patients often choose to self-pack the nose.</p>	<p>Level of evidence: III</p> <p>Strength of recommendation: Weak</p> <p>Agreement: 93%</p>
<p>The expert panel recommends that HHT-related epistaxis is not an absolute contraindication to anticoagulant/antiplatelet therapy.</p>	<p>Level of evidence: III</p> <p>Strength of</p>

<p>Anticoagulant/antiplatelet therapy can increase the risk of epistaxis and the decision to use these agents should be based on the individual patient risk and benefits.</p>	<p>recommendation: Strong Agreement: 100%</p>
<p>Clinical Considerations: HHT-related epistaxis will seldom, if ever, lead to sudden death while the use of anticoagulants/antiplatelets may prevent catastrophic or life-threatening events. In most HHT patients in whom visceral sources for life-threatening hemorrhage (i.e, significant PAVMs and CVMs) have been ruled out, a trial of anticoagulation can be considered if indicated. Referral to an otorhinolaryngologist with expertise in HHT should be considered, prior to starting anticoagulation therapy, to create a prior treatment plan in the event of a catastrophic bleeding event and to consider preventive surgical procedures.</p>	

References

1. Shah RK, Dhingra JK, Shapshay SM. Hereditary hemorrhagic telangiectasia: a review of 76 cases. *Laryngoscope* 2002; 112(5): 767-773.
2. Plauchu H, de Chadarevian JP, Bideau A, Robert JM. Age-related clinical profile of hereditary hemorrhagic telangiectasia in an epidemiologically recruited population. *Am J Med Genet* 1989; 32(3): 291-297.
3. Pasculli G, Resta F, Guastamacchia E, Di Gennaro L, Suppressa P, Sabba C. Health-related quality of life in a rare disease: hereditary hemorrhagic telangiectasia (HHT) or Rendu-Osler-Weber disease. *Qual Life Res* 2004; 13(10): 1715-1723.
4. McCaffrey TV, Kern EB, Lake CF. Management of epistaxis in hereditary hemorrhagic telangiectasia. Review of 80 cases. *Arch Otolaryngol* 1977; 103(11): 627-630.
5. McCabe WP, Kelly AP, Jr. Management of epistaxis in Osler-Weber-Rendu disease: recurrence of telangiectases within a nasal skin graft. *Plast Reconstr Surg* 1972; 50(2): 114-118.
6. Bergler W, Sadick H, Gotte K, Riedel F, Hormann K. Topical estrogens combined with argon plasma coagulation in the management of epistaxis in hereditary hemorrhagic telangiectasia. *Ann Otol Rhinol Laryngol* 2002; 111(3 Pt 1): 222-228.
7. Klepfish A, Berrebi A, Schattner A. Intranasal tranexamic acid treatment for severe epistaxis in hereditary hemorrhagic telangiectasia. *Arch Intern Med* 2001; 161(5): 767.
8. Mahoney EJ, Shapshay SM. Nd-YAG laser photocoagulation for epistaxis associated with hereditary hemorrhagic telangiectasia. *Laryngoscope* 2005; 115(2): 373-375.
9. Werner JA, Lippert BM, Geisthoff UW, Rudert H. [Nd:YAG laser therapy of recurrent epistaxis in hereditary hemorrhagic telangiectasia]. *Laryngorhinootologie* 1997; 76(8): 495-501.
10. Karapantzos I, Tsimpiris N, Goulis DG, Van Hoecke H, Van Cauwenberge P, Danielides V. Management of epistaxis in hereditary hemorrhagic telangiectasia by

Nd:YAG laser and quality of life assessment using the HR-QoL questionnaire. *Eur Arch Otorhinolaryngol* 2005; 262(10): 830-833.

11. Bergler W, Riedel F, Baker-Schreyer A, Juncker C, Hormann K. Argon plasma coagulation for the treatment of hereditary hemorrhagic telangiectasia. *Laryngoscope* 1999; 109(1): 15-20.
12. Siegel MB, Keane WM, Atkins JF, Jr., Rosen MR. Control of epistaxis in patients with hereditary hemorrhagic telangiectasia. *Otolaryngol Head Neck Surg* 1991; 105(5): 675-679.
13. Fiorella ML, Ross D, Henderson KJ, White RI, Jr. Outcome of septal dermoplasty in patients with hereditary hemorrhagic telangiectasia. *Laryngoscope* 2005; 115(2): 301-305.
14. Lund VJ, Howard DJ. Closure of the nasal cavities in the treatment of refractory hereditary haemorrhagic telangiectasia. *J Laryngol Otol* 1997; 111(1): 30-33.
15. Hitchings AE, Lennox PA, Lund VJ, Howard DJ. The effect of treatment for epistaxis secondary to hereditary hemorrhagic telangiectasia. *Am J Rhinol* 2005; 19(1): 75-78.
16. Gluckman JL, Portugal LG. Modified Young's procedure for refractory epistaxis due to hereditary hemorrhagic telangiectasia. *Laryngoscope* 1994; 104(9): 1174-1177.
17. Fischer M, Dietrich U, Labisch C, Zanella FE, Jahnke K. [Critical evaluation of vascular embolization in patients with Rendu-Osler disease]. *Laryngorhinootologie* 1997; 76(8): 490-494.
18. Elden L, Montanera W, Terbrugge K, Willinsky R, Lasjaunias P, Charles D. Angiographic embolization for the treatment of epistaxis: a review of 108 cases. *Otolaryngol Head Neck Surg* 1994; 111(1): 44-50.
19. Borsik M, Herbreteau D, Deffrennes D, Guichard JP, Aymard A, Merland JJ, Tran Ba Huy P. [Treatment of epistaxis in Rendu-Osler disease by intramucosal injection of ethibloc]. *Ann Otolaryngol Chir Cervicofac* 1992; 109(5): 273-276.
20. Jankowski R, Beaudouin E, Kanny G, Wayoff M, Moneret-Vautrin DA. [Hypersensitivity accidents to thrombin following the use of biological glues]. *Ann Otolaryngol Chir Cervicofac* 1992; 109(2): 95-99.
21. Vase P. Estrogen treatment of hereditary hemorrhagic telangiectasia. A double-blind controlled clinical trial. *Acta Med Scand* 1981; 209(5): 393-396.
22. Geisthoff UW. Clinical aspects of hereditary hemorrhagic telangiectasia. *Habilitation thesis, University of the Saarland, Homburg/Saar* 2006.
23. Andersen PJ, Kjeldsen AD, Nepper-Rasmussen J. Selective embolization in the treatment of intractable epistaxis. *Acta Otolaryngol* 2005; 125(3): 293-297.

Cerebral Vascular Malformations

Definition

The term cerebral vascular malformation (CVM) refers to a variety of vascular abnormalities, classified based on morphology, including: (1) arteriovenous malformations (CAVM) (including microAVMs measuring less than 1 cm in size); (2) cavernous malformations; (3) venous angiomas/developmental venous anomalies (DVA); (4) capillary telangiectasia, enlarged capillary-sized vessels; (5) vein of Galen malformations; (6) high flow pial fistulae (AVF); and (7) mixed malformations [1]. All of these types of CVMs can be found in HHT patients, though typically HHT is associated with CAVMs, AVFs, microAVMs and telangiectasia [2].

Background

Approximately 23% of HHT patients will harbour a CVM [3-5]. The rationale for screening for CVMs in HHT, is that screening will detect a treatable CVM prior to the development of a life-threatening or debilitating complication. We therefore reviewed the evidence regarding complications of CVMs, the performance of screening tests and the effectiveness of treatment for CVMs. Given the rarity of HHT-related CVMs, most of the evidence reviewed relates to the more common sporadic CVMs.

The bleeding risk of CVMs in HHT has been estimated retrospectively at approximately 0.5% per year[6], though there are no prospective natural history studies. In larger series of sporadic CAVMs [7], the annual rate of rupture is 2-4%/year[7]. Based on case series, CAVMs and AVF appear to have a more aggressive natural history, while CM, capillary telangiectasia and DVA, also reported to occur in HHT[4], appear to have a more benign natural history[3, 6, 8-10]. There are several case series and reports of catastrophic hemorrhagic sequelae of CVMs and spinal AVFs occurring during childhood [5, 11-14]. Rarely, spontaneous resolution of CVMs has been reported [15, 16].

The typical imaging features of HHT CVMs include the presence of either multiple, cortical, micro AVMs or AVFs harboring single feeding arteries and single draining veins [8-10]. Catheter angiography remains the gold standard for diagnosis of most types of CVMs, but carries a 0.5% risk of permanent stroke[17]. Magnetic resonance imaging (MRI) is considered to be a safe, non-invasive modality to screen for CVMs, but unfortunately there are no screening studies assessing its performance in HHT. MRI screening studies for non-HHT CVMs have been limited by small size, retrospective design and lack of blinding to clinical status, but suggest sensitivity of 80-95% for medium to large sized CVMs[18-20]. MRI is less sensitive for the detection of micro AVMs[20] but the addition of contrast enhancement (gadolinium for patients > 2 years of age) to MRI sequences increases the sensitivity for microAVMs. The inclusion of sequences designed to detect blood products (currently gradient echo sequences) also increases the sensitivity of MRI for microAVMs and signs of asymptomatic hemorrhage [11]. "False-positive" results may occur when other types of CVMs are encountered including telangiectasias which have a favorable natural history[4] and for which no further invasive imaging is required. Transcranial doppler (TCD) ultrasonography has also been used to screen for CVMs, [21, 22] with reported sensitivity of approximately

80% for medium to large-sized CVMs, but studies are limited by sample size and design. No evidence exists for follow-up screening after an initial negative study, as there is no evidence to suggest that adult patients with HHT develop new CVMs.

MRI provides a relatively safe, sensitive testing modality to identify CVMs in children[23]. While MRI itself poses little risk, the expert panel acknowledges the risk related to sedation/anaesthesia of children for diagnostic procedures. Of greatest concern is the risk of respiratory depression, but this should be minimized with appropriate cardiorespiratory monitoring. No evidence exists at this time to recommend follow-up screening after an initial negative study during childhood, but consideration should be given to one adulthood MRI following initial negative childhood MRI.

The expert panel agreed CVM obliteration is required to effectively eliminate the future risk of hemorrhage. Although treatment may provide a large relative risk reduction for cerebral bleeding, procedural risks are significant. There are no published studies of the efficacy or safety of any form of treatment of CVMs in HHT patients. However, several large case series (>200 patients, mostly single-center) of embolization, microsurgery and stereotactic radiation in non-HHT CAVMs, show widely ranging effectiveness for each modality[4, 9, 12, 24-34]. Based on this, as well as expert experience, the expert panel agreed that effective treatment strategies include embolization, microsurgery and stereotactic radiation, or combinations of these. With the rarity of CVMs and the associated risks of treatment, the expert panel agreed that each case should be managed in an individualized manner and that decisions about invasive testing and therapy should occur at centers with significant experience and expertise in all treatment modalities. Though there is no evidence regarding differences in outcomes according to expertise in management of these cases, the expert panel agreed that centers with experience in HHT-related CVMs will be more aware of important issues related to the care of HHT patients and likely to have better outcomes of surgical and other procedures.

CVMs occur in infants and children with HHT[2, 5, 10, 13, 35, 36]. Before the age of 6 these malformations tend to be high flow pial fistulae (cerebral or spinal cord AVF)[2]. Expert opinion is that these malformations have a more aggressive natural history than nidus type CAVMs, including presenting events such as intracerebral hemorrhage, cognitive deficit, cardiac insufficiency, epilepsy and hydrocephalus[2, 10, 35, 36]. Embolization or microsurgical obliteration of these high flow pial fistulae in children may therefore be of significant benefit when performed by a neurovascular center with expertise in these techniques in children.

There is no evidence to guide the management of CVMs during pregnancy and delivery, as there is no good evidence regarding the risk of CVM complications or treatment during pregnancy and delivery.

Recommendations

The expert panel recommends that the clinician screen adult patients with possible or definite HHT for cerebral vascular malformations.	Level of evidence: III Strength of
--	---------------------------------------

<p>Clinical Considerations: Dissension resulted primarily from the lack of evidence of treatment effectiveness for asymptomatic CVMs in HHT and therefore the lack of evidence for benefit of screening.</p> <p>The specifics regarding screening method are detailed in the next recommendation. There is no evidence for any role for repeat MRI screening in adults, after an initial negative study. The likelihood of detecting a CVM will be less in patients with only a “possible” diagnosis of HHT, but that screening in these patients may be reasonable if the diagnosis of HHT cannot be ruled out genetically.</p> <p>The expert panel could not generate a recommendation regarding screening for spinal AVFs, given their rarity and absence of evidence. However, if screening for spinal AVFs is being considered in children with HHT, a sagittal T2 MRI of the spine would be appropriate.</p>	<p>recommendation: Weak</p> <p>Agreement: 77%</p>
<p>The expert panel recommends the use of MRI for cerebral vascular malformation screening in adults with possible or definite HHT using a protocol with and without contrast administration and using sequences that detect blood products, to maximize sensitivity.</p> <p>Clinical Considerations: If patients have received previous embolization, coil compatibility with MRI must be confirmed prior to MR examination. The expert panel acknowledges that the optimum age for adult screening remains unknown but felt that age 18 was appropriate as patients enter adulthood. In the presence of a negative MRI in adulthood no further screening tests are suggested. There may be additional benefits to performing an MRI at initial assessment, in the detection of infarcts and other CNS complications of HHT.</p>	<p>Level of evidence: III</p> <p>Strength of recommendation: Weak</p> <p>Agreement: 100%</p>
<p>The expert panel recommends that the clinician screen children with possible or definite HHT for cerebral vascular malformations in the first 6 months of life (or at time of diagnosis) with an unenhanced MRI, and refer all patients with an MRI positive for these lesions to a center with neurovascular expertise for consideration of invasive testing and further management.</p> <p>Clinical Considerations: Dissension resulted primarily from the lack of evidence of treatment effectiveness for asymptomatic CVMs in HHT and therefore the lack of evidence for benefit of screening, as well as greater risk of</p>	<p>Level of evidence: III</p> <p>Strength of recommendation: Weak</p> <p>Agreement: 64%</p>

<p>screening in children.</p> <p>When MR screening is performed with the use of sedation and anesthesia in young children, it is necessary to monitor cardiorespiratory parameters during the procedure and to provide an equivalent standard of care as that provided in an operating room. The technique utilized to sedate/anesthetize infants for MRI should be performed in accordance with local expertise and no undue risk be taken to obtain such a screening test. The MRI would generally be planned at the time of HHT diagnosis, preferably before 6 months of age when the risk benefit ratio would be optimal.</p>	
<p>The expert panel recommends that adults presenting with an acute hemorrhage secondary to a cerebral vascular malformation be considered for definitive treatment in a center with neurovascular expertise.</p>	<p>Level of evidence: III</p> <p>Strength of recommendation: Strong</p> <p>Agreement: 94%</p>
<p>The expert panel recommends that all other adults with cerebral vascular malformations be referred to a center with neurovascular expertise to be considered for invasive testing and individualized management.</p> <p>Clinical Considerations: The expert panel recognizes that asymptomatic CVMs discovered during screening of HHT patients may carry a more favorable natural history. These patients should be managed on an individualized basis. Since some CVMs may carry a favorable natural history, referral to a center with neurovascular expertise prior to performing invasive imaging (catheter angiography) may minimize unnecessary testing.</p>	<p>Level of evidence: III</p> <p>Strength of recommendation: Strong</p> <p>Agreement: 84%</p>
<p>The expert panel recommends that pregnant women with suspected or confirmed HHT harboring an asymptomatic CAVM during pregnancy have definitive treatment of their CAVM deferred until after delivery of their fetus. The expert panel recommends that the delivery of the fetus follow obstetrical principles.</p>	<p>Level of evidence: III</p> <p>Strength of Recommendation: Weak</p> <p>Agreement: 80%</p>

References

1. Ojemann RG, Ogilvy CS, Crowell RM, Heros RC. Surgical Management of Neurovascular Disease. Williams and Wilkins, Baltimore, 1995.
2. Krings T, Ozanne A, Chng SM, Alvarez H, Rodesch G, Lasjaunias PL. Neurovascular phenotypes in hereditary haemorrhagic telangiectasia patients according to age. Review of 50 consecutive patients aged 1 day-60 years. *Neuroradiology* 2005; 47(10): 711-720.

3. Maher CO, Piepgras DG, Brown RD, Jr., Friedman JA, Pollock BE. Cerebrovascular manifestations in 321 cases of hereditary hemorrhagic telangiectasia. *Stroke* 2001; 32(4): 877-882.
4. Morgan MK, Zurin AA, Harrington T, Little N. Changing role for preoperative embolisation in the management of arteriovenous malformations of the brain. *J Clin Neurosci* 2000; 7(6): 527-530.
5. Fulbright RK, Chaloupka JC, Putman CM, Sze GK, Merriam MM, Lee GK, Fayad PB, Awad IA, White RI, Jr. MR of hereditary hemorrhagic telangiectasia: prevalence and spectrum of cerebrovascular malformations. *AJNR Am J Neuroradiol* 1998; 19(3): 477-484.
6. Willemse RB, Mager JJ, Westermann CJ, Overtoom TT, Mauser H, Wolbers JG. Bleeding risk of cerebrovascular malformations in hereditary hemorrhagic telangiectasia. *J Neurosurg* 2000; 92(5): 779-784.
7. MacDonald RL, Stoodley M, Weir B. Vascular malformations of the central nervous system. *Neurosurgery Quarterly* 2001; 11(4): 231-247.
8. Matsubara S, Mandzia JL, ter Brugge K, Willinsky RA, Faughnan ME. Angiographic and clinical characteristics of patients with cerebral arteriovenous malformations associated with hereditary hemorrhagic telangiectasia. *AJNR Am J Neuroradiol* 2000; 21(6): 1016-1020.
9. Willinsky RA, Lasjaunias P, Terbrugge K, Burrows P. Multiple cerebral arteriovenous malformations (AVMs). Review of our experience from 203 patients with cerebral vascular lesions. *Neuroradiology* 1990; 32(3): 207-210.
10. Morgan T, McDonald J, Anderson C, Ismail M, Miller F, Mao R, Madan A, Barnes P, Hudgins L, Manning M. Intracranial hemorrhage in infants and children with hereditary hemorrhagic telangiectasia (Osler-Weber-Rendu syndrome). *Pediatrics* 2002; 109(1): E12.
11. Cullen S, Alvarez H, Rodesch G, Lasjaunias P. Spinal arteriovenous shunts presenting before 2 years of age: analysis of 13 cases. *Childs Nerv Syst* 2006; 22(9): 1103-1110.
12. Berman MF, Hartmann A, Mast H, Sciacca RR, Mohr JP, Pile-Spellman J, Young WL. Determinants of resource utilization in the treatment of brain arteriovenous malformations. *AJNR Am J Neuroradiol* 1999; 20(10): 2004-2008.
13. Mei-Zahav M, Letarte M, Faughnan ME, Abdalla SA, Cymerman U, MacLusky IB. Symptomatic children with hereditary hemorrhagic telangiectasia: a pediatric center experience. *Arch Pediatr Adolesc Med* 2006; 160(6): 596-601.
14. Mandzia JL, terBrugge KG, Faughnan ME, Hyland RH. Spinal cord arteriovenous malformations in two patients with hereditary hemorrhagic telangiectasia. *Childs Nerv Syst* 1999; 15(2-3): 80-83.
15. Leung KM, Agid R, terBrugge K. Spontaneous regression of a cerebral arteriovenous malformation in a child with hereditary hemorrhagic telangiectasia. Case report. *J Neurosurg* 2006; 105(5 Suppl): 428-431.
16. Cloft HJ. Spontaneous regression of cerebral arteriovenous malformation in hereditary hemorrhagic telangiectasia. *AJNR Am J Neuroradiol* 2002; 23(6): 1049-1050.
17. Willinsky RA, Taylor SM, Terbrugge K, Farb RI, Tomlinson G, Montanera W. Neurologic complications of cerebral angiography: prospective analysis of 2,899 procedures and review of the literature. *Radiology* 2003; 227(2): 522-528.

18. Gauvrit JY, Oppenheim C, Nataf F, Naggara O, Trystram D, Munier T, Fredy D, Pruvo JP, Roux FX, Leclerc X, Meder JF. Three-dimensional dynamic magnetic resonance angiography for the evaluation of radiosurgically treated cerebral arteriovenous malformations. *Eur Radiol* 2006; 16(3): 583-591.
19. Mori H, Aoki S, Okubo T, Hayashi N, Masumoto T, Yoshikawa T, Tago M, Shin M, Kurita H, Abe O, Ohtomo K. Two-dimensional thick-slice MR digital subtraction angiography in the assessment of small to medium-size intracranial arteriovenous malformations. *Neuroradiology* 2003; 45(1): 27-33.
20. Mukherji SK, Quisling RG, Kubilis PS, Finn JP, Friedman WA. Intracranial arteriovenous malformations: quantitative analysis of magnitude contrast MR angiography versus gradient-echo MR imaging versus conventional angiography. *Radiology* 1995; 196(1): 187-193.
21. Mast H, Mohr JP, Thompson JL, Osipov A, Trocio SH, Mayer S, Young WL. Transcranial Doppler ultrasonography in cerebral arteriovenous malformations. Diagnostic sensitivity and association of flow velocity with spontaneous hemorrhage and focal neurological deficit. *Stroke* 1995; 26(6): 1024-1027.
22. Sommer C, Mullges W, Ringelstein EB. Noninvasive assessment of intracranial fistulas and other small arteriovenous malformations. *Neurosurgery* 1992; 30(4): 522-528.
23. Lundby B, Gordon P, Hugo F. MRI in children given gadodiamide injection: safety and efficacy in CNS and body indications. *Eur J Radiol* 1996; 23(3): 190-196.
24. Haw CS, terBrugge K, Willinsky R, Tomlinson G. Complications of embolization of arteriovenous malformations of the brain. *J Neurosurg* 2006; 104(2): 226-232.
25. Lawton MT, Du R, Tran MN, Achrol AS, McCulloch CE, Johnston SC, Quinnine NJ, Young WL. Effect of presenting hemorrhage on outcome after microsurgical resection of brain arteriovenous malformations. *Neurosurgery* 2005; 56(3): 485-493; discussion 485-493.
26. Lunsford LD, Kondziolka D, Flickinger JC, Bissonette DJ, Jungreis CA, Maitz AH, Horton JA, Coffey RJ. Stereotactic radiosurgery for arteriovenous malformations of the brain. *J Neurosurg* 1991; 75(4): 512-524.
27. Meisel HJ, Mansmann U, Alvarez H, Rodesch G, Brock M, Lasjaunias P. Cerebral arteriovenous malformations and associated aneurysms: analysis of 305 cases from a series of 662 patients. *Neurosurgery* 2000; 46(4): 793-800; discussion 800-792.
28. Pollock BE, Flickinger JC, Lunsford LD, Bissonette DJ, Kondziolka D. Hemorrhage risk after stereotactic radiosurgery of cerebral arteriovenous malformations. *Neurosurgery* 1996; 38(4): 652-659; discussion 659-661.
29. Suzuki J, Onuma T, Kayama T. Surgical treatment of intracranial arteriovenous malformation. *Neurol Res* 1982; 4(3-4): 191-207.
30. Schwartz M, Sixel K, Young C, Kemeny A, Forster D, Walton L, Franssen E. Prediction of obliteration of arteriovenous malformations after radiosurgery: the obliteration prediction index. *Can J Neurol Sci* 1997; 24(2): 106-109.
31. Taylor CL, Dutton K, Rappard G, Pride GL, Replogle R, Purdy PD, White J, Giller C, Kopitnik TA, Jr., Samson DS. Complications of preoperative embolization of cerebral arteriovenous malformations. *J Neurosurg* 2004; 100(5): 810-812.
32. Yoshimoto T, Kayama T, Suzuki J. Treatment of cerebral arteriovenous malformation. *Neurosurg Rev* 1986; 9(4): 279-285.

33. Zhao J, Wang S, Li J, Qi W, Sui D, Zhao Y. Clinical characteristics and surgical results of patients with cerebral arteriovenous malformations. *Surg Neurol* 2005; 63(2): 156-161; discussion 161.
34. Spetzler RF, Martin NA, Carter LP, Flom RA, Raudzens PA, Wilkinson E. Surgical management of large AVM's by staged embolization and operative excision. *J Neurosurg* 1987; 67(1): 17-28.
35. Weon YC, Yoshida Y, Sachet M, Mahadevan J, Alvarez H, Rodesch G, Lasjaunias P. Supratentorial cerebral arteriovenous fistulas (AVFs) in children: review of 41 cases with 63 non choroidal single-hole AVFs. *Acta Neurochir (Wien)* 2005; 147(1): 17-31; discussion 31.
36. Yoshida Y, Weon YC, Sachet M, Mahadevan J, Alvarez H, Rodesch G, Lasjaunias P. Posterior cranial fossa single-hole arteriovenous fistulae in children: 14 consecutive cases. *Neuroradiology* 2004; 46(6): 474-481.

Pulmonary Arteriovenous Malformations

Background

PAVMs are present in approximately 15-50% of people with HHT and have been associated with life-threatening complications, as previously reviewed [1, 2]. The rationale for screening HHT patients for PAVMs is that screening will detect a treatable PAVM prior to the development of a life-threatening or debilitating complication. We therefore reviewed the evidence regarding complications of PAVMs, the performance of screening tests and the effectiveness of treatment for PAVMs.

PAVMs have been shown to be associated with disabling and life-threatening complications, such as stroke, TIA, cerebral abscess, massive hemoptysis and spontaneous hemothorax [1, 3-6] in retrospective series. The neurologic complications are presumed to occur via paradoxical embolization through PAVMs whereas the hemorrhagic complications occur due to spontaneous PAVM rupture. These complications have been demonstrated in largely adult series of HHT patients, though they have also been demonstrated in a pediatric HHT series[7], albeit smaller in size. There have also been small series reporting these same complications during pregnancy [8, 9] and the expert panel agreed that the complication risk appears to be greater during pregnancy.

Since clinical symptoms and signs of PAVMs are frequently absent prior to the development of complications, a number of screening tests have been studied, including physiologic methods of measurement of intrapulmonary shunt as well as multiple different imaging modalities. In the one comparative study (Table 3), transthoracic contrast echocardiography with agitated saline (TTCE) has been demonstrated to have the best combination of high sensitivity [2] and low-risk[10, 11] amongst screening tests for PAVMs in adults with HHT, when compared to the reference standard tests (CT and pulmonary angiography). There have been no comparative screening studies for PAVMs in children with HHT.

Embolization has been shown in several non-controlled series [3, 5, 12-16] to be efficacious and to have a good safety profile, with only rare PAVM-related complications during 5-10 year follow-up (Table 4). In the short-term, these studies demonstrated very high rates of immediate technical success and significant improvement in oxygenation (Table 4). Longer term post-embolization, reperfusion did occur in up to 15% and growth of small PAVMs in up to 18% (Table 4) but clinical complications were very rare. These series primarily reported outcomes for treatment of PAVMs with feeding artery diameter of 3 mm or greater, though expert experience suggests that embolization of smaller PAVMs (2-3mm) has similar outcomes. The safety and efficacy were similar for large PAVMs in adults[17] as well as for PAVMs in children[7], though there is little experience with embolization of PAVMs in children under the age of 4 years. There is only one small case series of embolization during pregnancy[18], suggesting reasonable safety. Though there is no evidence regarding differences in outcomes according to expertise in embolization of PAVMs, the expert panel agreed that

centers with experience in this procedure are more likely to have better outcomes than inexperienced centers.

The long-term follow-up of PAVMs is described using CT of the thorax. This allows detection of reperfusion by non-involution of aneurismal sac at approximately 1 year post-embolization and also detection of growth of small residual PAVMs, which are frequent in HHT[5]. TTCE has been shown to not be useful post-embolization, given that it remains positive in approximately 90% of patients post-embolization[19].

Recommendations

<p>The expert panel recommends that clinicians screen all patients with possible or confirmed HHT for PAVMs.</p> <p>Clinical considerations: Screening should be performed at the time of initial clinical evaluation for HHT. Although less evidence exists in children, the expert panel included children in the screening recommendation, since they are also at risk of life-threatening complications and treatment appears to be similarly effective.</p> <p>In patients with negative initial screening, repeat screening should be considered after puberty, after pregnancy, within 5 years preceding planned pregnancy and otherwise every 5-10 years.</p>	<p>Level of evidence: III</p> <p>Strength of recommendation: Strong</p> <p>Agreement: 96%</p>
<p>The expert panel recommends that clinicians use transthoracic contrast echocardiography as the initial screening test for PAVMs.</p> <p>Clinical Considerations: Screening should be performed by clinicians with significant expertise in HHT, usually in an HHT center of excellence, to achieve the accuracy and low-risks reported in the literature. TTCE is considered positive if there is detection of any bubbles in the left atrium. Positive screening should be confirmed with unenhanced multidetector thoracic CT with thin-cut (eg. 1-2mm) reconstructions. CT was not recommended as a screening test, due to the associated radiation exposure, but could be considered for screening in centers without expertise in TTCE for PAVM screening.</p> <p>In children, the choice of screening tests should be decided on a case by case basis, but may include clinical evaluation (for cyanosis, dyspnea, clubbing), supine and upright pulse oximetry, chest radiography and/or TTCE.</p>	<p>Level of evidence: II</p> <p>Strength of recommendation: Weak</p> <p>Agreement: 96%</p>

<p>The expert panel recommends that clinicians treat PAVMs with transcatheter embolotherapy.</p> <p>Clinical Considerations: The recommendation applies to all adults with PAVMs and children with symptomatic PAVMs. The decision to treat in <i>asymptomatic children</i> (no dyspnea, no exercise intolerance, no growth delay, no cyanosis or clubbing, no previous complication) should be made on a case by case basis. The selection of PAVMs for embolization is based on feeding artery diameter, generally 3mm or greater, though targeting PAVMs with feeding artery diameter as low as 2 mm may be appropriate.</p> <p>This procedure should be performed by clinicians with significant expertise in embolizing PAVMs, usually in an HHT center of excellence, to achieve the effectiveness and low-risks reported in the literature. This is particularly relevant when considering embolization in rare or higher risk situations, such as during pregnancy and in patients with mild-moderate pulmonary hypertension. The panel agrees there is no role for surgical management of PAVMs, other than in the management of life-threatening bleeding in a center where embolization expertise is unavailable.</p>	<p>Level of evidence: II</p> <p>Strength of recommendation: Strong</p> <p>Agreement: 96%</p>
<p>The expert panel recommends that clinicians provide the following long-term advice to patients with documented pulmonary AVMs (treated or untreated):</p> <ol style="list-style-type: none"> 1. Antibiotic prophylaxis for procedures with risk of bacteremia 2. When IV access is in place, take extra care to avoid IV air 3. Avoidance of SCUBA diving <p>Clinical Considerations: The rationale for recommending prophylactic antibiotics for bacteremic procedures in people with PAVMs, is based on expert opinion that cerebral abscess is frequent in these patients (approximately 10% before PAVM diagnosis), that cerebral abscess in these patients occurs primarily as a complication of bacteremic procedures, the fact that cerebral abscess is associated with considerable morbidity and mortality and that this precaution is low-risk. The AHA guidelines for prevention of bacterial endocarditis should be followed for choice of antibiotics.</p> <p>Similarly, careful avoidance of intravenous air bubbles is recommended to prevent cerebral air embolism, and this could include an in-line filter. There are only theoretical arguments</p>	<p>Level of evidence: III</p> <p>Strength of recommendation: Weak</p> <p>Agreement: 87%</p>

<p>for avoidance of SCUBA suggesting that there may be an increased risk of complications of decompression in patients with PAVMs.</p> <p>These precautions should be followed life-long, regardless of size of PAVMs, even once PAVMs are treated. These precautions should also be considered in HHT patients in whom PAVMs have not been excluded or in whom microscopic PAVMs are suspected (for example, detected on TTCE but not detectable on CT).</p>	
<p>The expert panel recommends that clinicians provide long-term follow-up for patients who have PAVMs, in order to detect growth of untreated PAVMs and also reperfusion of treated AVMs.</p> <p>Clinical Considerations: Follow-up allows the identification of embolized PAVMs that have reperfused and other PAVMs that have grown large enough to be considered for embolization. Multidetector thoracic CT with thin-section reconstruction (1-2mm) should be undertaken within 6-12 months after embolization and then approximately every 3 years after embolization.</p> <p>For patients with only small untreated PAVMs and in patients with suspected microscopic PAVMs (for example, detected on TTCE but not detectable on CT), the follow-up period should be determined on a case by case basis (approximately every 1-5 years) with CT (as above), with consideration for limiting radiation exposure.</p>	<p>Level of evidence: II</p> <p>Strength of recommendation: Strong</p> <p>Agreement: 100%</p>

References

1. Gossage JR, Kanj G. Pulmonary arteriovenous malformations. A state of the art review. *Am J Respir Crit Care Med* 1998; 158(2): 643-661.
2. Cottin V, Plauchu H, Bayle JY, Barthelet M, Revel D, Cordier JF. Pulmonary arteriovenous malformations in patients with hereditary hemorrhagic telangiectasia. *Am J Respir Crit Care Med* 2004; 169(9): 994-1000.
3. Mager JJ, Overtoom TT, Blauw H, Lammers JW, Westermann CJ. Embolotherapy of pulmonary arteriovenous malformations: long-term results in 112 patients. *J Vasc Interv Radiol* 2004; 15(5): 451-456.
4. Moussouttas M, Fayad P, Rosenblatt M, Hashimoto M, Pollak J, Henderson K, Ma TY, White RI. Pulmonary arteriovenous malformations: cerebral ischemia and neurologic manifestations. *Neurology* 2000; 55(7): 959-964.

5. Pollak JS, Saluja S, Thabet A, Henderson KJ, Denbow N, White RI, Jr. Clinical and anatomic outcomes after embolotherapy of pulmonary arteriovenous malformations. *J Vasc Interv Radiol* 2006; 17(1): 35-44; quiz 45.
6. Swanson KL, Prakash UB, Stanson AW. Pulmonary arteriovenous fistulas: Mayo Clinic experience, 1982-1997. *Mayo Clin Proc* 1999; 74(7): 671-680.
7. Faughnan ME, Thabet A, Mei-Zahav M, Colombo M, Maclusky I, Hyland RH, Pugash RA, Chait P, Henderson KJ, White RI, Jr. Pulmonary arteriovenous malformations in children: outcomes of transcatheter embolotherapy. *J Pediatr* 2004; 145(6): 826-831.
8. Shovlin CL, Winstock AR, Peters AM, Jackson JE, Hughes JM. Medical complications of pregnancy in hereditary haemorrhagic telangiectasia. *QJM* 1995; 88(12): 879-887.
9. FERENCE BA, Shannon TM, White RI, Jr., Zawin M, Burdge CM. Life-threatening pulmonary hemorrhage with pulmonary arteriovenous malformations and hereditary hemorrhagic telangiectasia. *Chest* 1994; 106(5): 1387-1390.
10. Nanthakumar K, Graham AT, Robinson TI, Grande P, Pugash RA, Clarke JA, Hutchison SJ, Mandzia JL, Hyland RH, Faughnan ME. Contrast echocardiography for detection of pulmonary arteriovenous malformations. *Am Heart J* 2001; 141(2): 243-246.
11. Barzilai B, Waggoner AD, Spessert C, Picus D, Goodenberger D. Two-dimensional contrast echocardiography in the detection and follow-up of congenital pulmonary arteriovenous malformations. *Am J Cardiol* 1991; 68(15): 1507-1510.
12. White RI, Jr., Lynch-Nyhan A, Terry P, Buescher PC, Farnlett EJ, Charnas L, Shuman K, Kim W, Kinnison M, Mitchell SE. Pulmonary arteriovenous malformations: techniques and long-term outcome of embolotherapy. *Radiology* 1988; 169(3): 663-669.
13. Dutton JA, Jackson JE, Hughes JM, Whyte MK, Peters AM, Ussov W, Allison DJ. Pulmonary arteriovenous malformations: results of treatment with coil embolization in 53 patients. *AJR Am J Roentgenol* 1995; 165(5): 1119-1125.
14. Chilvers ER, Whyte MK, Jackson JE, Allison DJ, Hughes JM. Effect of percutaneous transcatheter embolization on pulmonary function, right-to-left shunt, and arterial oxygenation in patients with pulmonary arteriovenous malformations. *Am Rev Respir Dis* 1990; 142(2): 420-425.
15. Gupta P, Mordin C, Curtis J, Hughes JM, Shovlin CL, Jackson JE. Pulmonary arteriovenous malformations: effect of embolization on right-to-left shunt, hypoxemia, and exercise tolerance in 66 patients. *AJR Am J Roentgenol* 2002; 179(2): 347-355.
16. Prasad V, Chan RP, Faughnan ME. Embolotherapy of pulmonary arteriovenous malformations: efficacy of platinum versus stainless steel coils. *J Vasc Interv Radiol* 2004; 15(2 Pt 1): 153-160.
17. Lee DW, White RI, Jr., Egglin TK, Pollak JS, Fayad PB, Wirth JA, Rosenblatt MM, Dickey KW, Burdge CM. Embolotherapy of large pulmonary arteriovenous malformations: long-term results. *Ann Thorac Surg* 1997; 64(4): 930-939; discussion 939-940.
18. Gershon AS, Faughnan ME, Chon KS, Pugash RA, Clark JA, Bohan MJ, Henderson KJ, Hyland RH, White RI, Jr. Transcatheter embolotherapy of maternal pulmonary arteriovenous malformations during pregnancy. *Chest* 2001; 119(2): 470-477.

19. Lee WL, Graham AF, Pugash RA, Hutchison SJ, Grande P, Hyland RH, Faughnan ME. Contrast echocardiography remains positive after treatment of pulmonary arteriovenous malformations. *Chest* 2003; 123(2): 351-358.

Gastrointestinal Bleeding

Background

Although 80% of patients with HHT have gastric or small intestinal telangiectasia [1] on endoscopy or capsule examination, only 25-30% of patients will develop symptomatic GI bleeding [2-5] which usually does not present until the fifth or sixth decades of life. Patients rarely develop significant GI bleeding before 40 years of age [2-5]. Women are affected with GI bleeding in a ratio of 2-3:1 [6, 7].

Patients with HHT and GI bleeding may or may not be symptomatic, as the bleeding is usually in a slow, chronic and intermittent fashion, often without notable melena. Patients often have few symptoms until they become anemic. In severe cases, HHT GI bleeding causes morbidity, dependency on blood transfusions and increased mortality[6]. Severity of GI bleeding in HHT is generally based on severity of the anemia. Gastric and duodenal telangiectasia are more common than colonic telangiectasia and contribute more to overall GI bleeding and chronic anemia in HHT patients[8]. .

Presently, endoscopic evaluation is considered the gold standard test for evaluation of GI bleeding in HHT patients. Though the majority of patients with HHT will have GI telangiectasia, the utility of endoscopic evaluation is in the anemic or iron-deficient patient. The presence and number of gastric and duodenal telangiectasia have been shown to predict the presence and number of jejunal telangiectasia [7] and therefore, for diagnostic purposes, an esophagogastroduodenoscopy (EGD) is sufficient in most cases.

Management of GI bleeding in HHT involves treatment of the iron-deficiency/anemia and therapies to reduce GI bleeding. Treatment of anemia and iron deficiency includes aggressive iron replacement and blood transfusions as necessary. There are no studies of iron replacement in HHT, but experts agree that oral iron supplementation may be sufficient in some patients, though consideration of intravenous iron supplementation may be necessary in more severe cases. There have been no studies of erythropoietin therapy in HHT, but it is sometimes considered in severe cases, in combination with iron, in an attempt to accelerate treatment of the anemia.

Current treatment options to reduce chronic GI bleeding in HHT include hormonal therapy (estrogen-progesterone preparations or danacrine), anti-fibrinolytics (aminocaproic acid or tranexamic acid), other medications reported only as isolated case reports (tamoxifen, interferon, thalidomide and sirolimus) and endoscopic therapy. There is one small double-blind placebo-controlled crossover trial[9] (Table 5) of combination hormonal therapy (ethinylestradiol 0.050 mg plus norethisterone 1 mg) versus placebo, each for six months, in 10 patients with transfusion dependent severe GI bleeding. Five of the six HHT patients had no further GI bleeding while on treatment and, in the overall group, there was a significant decline in transfusion requirements. In a retrospective case series[6] of 43 HHT patients with GI bleeding, median haemoglobin improved significantly (8.6 to 9.8, p=0.0018) for the 23 patients treated with medical therapy (ethinyl estradiol/norethindrone in 19, danacrine in 2 and aminocaproic acid in 2). Though there are only other individual case reports[10] of danacrine in HHT GI bleeding,

it may be a reasonable alternative to estrogen/progesterone therapy in male patients, as it does not have feminizing effects. There is only individual case report evidence for antifibrinolytics for HHT-related GI bleeding [11], but there is expert experience suggesting benefit in these patients. Overall, there is insufficient evidence to recommend any medical therapy as first line therapy in these patients, given the potential side effects, however there may be a role for these agents when iron replacement is insufficient to control anemia.

There are small case series (Table 5) and expert experience suggesting that local endoscopic therapy, using argon plasma coagulation (APC) or ND-YAG laser, may be beneficial in reduction of HHT-related GI bleeding. In three small case series [12-14] of repeated ND-YAG therapy, transfusion requirements declined in more than 50% of patients. The expert panel agreed that though the reported series were primarily of the use of ND-YAG laser, that APC is the most effective method of endoscopic therapy currently available. Overall, there is insufficient evidence to recommend endoscopic therapy as first line therapy in HHT-related GI bleeding; however there may be a role for endoscopic therapy when iron replacement is insufficient to control anemia. There is no evidence or experience supporting cauterization of colonic telangiectasia, or for surgery or transcatheter embolotherapy in the routine management of HHT-related GI bleeding. Though there is no evidence regarding differences in outcomes according to expertise in endoscopic management of GI bleeding in HHT, the expert panel agreed that clinicians with experience in HHT-related GI bleeding will be better prepared to make decisions about when to treat GI telangiectasia in HHT and are likely to have better outcomes of these procedures.

There is no evidence of any benefit in altering nutrition or life style, or for screening for *Helicobacter pylori* in patients with HHT-related GI bleeding. HHT patients with GI bleeding should avoid anticoagulants and medications that alter platelet function. However, when other comorbidities require use of these medications, expert experience is that these can often be tolerated, especially when doses are kept as low as possible.

Recommendations

<p>The expert panel recommends that all patients over 35 years should have annual hemoglobin or hematocrit levels measured because of the increased risk of significant gastrointestinal bleeding with age. Directed endoscopic evaluation should be undertaken in patients with anemia disproportionate to epistaxis. The expert panel advises against gastrointestinal endoscopic investigations in patients with HHT and no evidence of anemia.</p>	<p>Level of evidence: III</p> <p>Strength of recommendation: Strong</p> <p>Agreement: 89%</p>
<p>Clinical Considerations: A blood test for haemoglobin and ferritin should be drawn as part of the annual physical examination with the family physician. The age of 35 is preferred as few people begin having problems with GI</p>	

<p>bleeding before 40 and this allows measurement of baseline hemoglobin to track GI losses. Patients over 50 years of age, particularly women, are considered at higher risk of HHT-related GI bleeding. Of note, fecal occult blood testing can be falsely positive due to GI transit of swallowed epistaxis and therefore this test is not useful.</p>	
<p>In HHT patients with suspected gastrointestinal bleeding, the expert panel recommends that an upper endoscopy be the first diagnostic test. The diagnosis of HHT-related gastrointestinal bleeding is made in the presence of anemia and endoscopic visualization of characteristic gastrointestinal telangiectasia in combination with clinical judgment.</p> <p>Clinical Considerations: HHT patients with anemia should be referred to clinicians with HHT expertise for endoscopic visualization to identify the source of their GI bleeding. Since the majority of the bleeding occurs in the stomach and proximal small intestine, an upper endoscopy is usually sufficient to diagnose upper GI telangiectasia. The clinician must be aware that the presence of characteristic GI telangiectasia does not necessarily indicate that they are the source of anemia or GI bleeding and does not preclude other sources of bleeding. Wireless capsule endoscopy may be considered when direct endoscopic visualization of the GI tract with upper and lower endoscopies does not adequately explain the anemia.</p> <p>It is uncommon for the GI telangiectasia in HHT to cause massive, acute GI bleeding. In HHT patients with acute GI bleeding, therefore, other causes should be considered first as in non-HHT patients.</p>	<p>Level of evidence: III</p> <p>Strength of recommendation: Strong</p> <p>Agreement: 90%</p>
<p>The expert panel recommends oral and/or IV iron supplementation as first line therapy for mild anemia and chronic bleeding secondary to HHT-related telangiectasia.</p> <p>Clinical Considerations: For replenishment of iron stores the clinician can select the oral iron formulation that is best tolerated by the patient, as long as the dosing is adequate. Often patients will require 6-12 months of, for example, ferrous fumarate 300mg OD, but the dose and duration are adjusted according to the patient's haemoglobin and ferritin response. If one oral iron preparation is not tolerated, then a trial of another should be considered. If oral iron replacement is insufficient or not tolerated, then intravenous iron, preferably iron sucrose, should next be considered.</p>	<p>Level of evidence: III</p> <p>Strength of recommendation: Weak</p> <p>Agreement: 97%</p>

<p>Hemoglobin and ferritin levels should be monitored regularly, with the frequency depending on the severity of the anemia, until both the anemia and iron deficiency are resolved. Some patients may require long-term or life-long iron supplementation. If additional therapy with erythropoietin is considered, patients should be screened and treated for PAVMs before initiating therapy, due to the thrombogenic risk of erythropoietin.</p>	
<p>The expert panel recommends against the use of multiple attempts at local endoscopic therapy because of the additive risk of adverse events without corresponding benefits.</p> <p>Clinical Considerations: The HHT patient with anemia not responding to iron supplementation should be referred to a clinician with expertise in endoscopic treatment of HHT patients, for consideration of one or two attempts to locally cauterize visible telangiectasia. This is most likely to be beneficial when performed with APC and by endoscopist with related experience. Since the majority of the bleeding occurs in the stomach and proximal small intestine, cauterization during upper endoscopy is most likely to be beneficial. If initial endoscopic cauterization is not beneficial in a given patient, further multiple attempts at endoscopic cauterization of GI telangiectasia are unlikely to be beneficial and yet will expose the patient to unwarranted risk. Specialized endoscopy, such as enteroscopy, or performing endoscopy during surgery, are not routinely used for treatment of HHT-related bleeding, but may be considered in cases where treatment of more distal lesions is being considered (distal to the duodenum and proximal to the terminal ileum).</p>	<p>Level of evidence: III</p> <p>Strength of recommendation: Weak</p> <p>Agreement: 90%</p>
<p>The expert panel recommends that the clinician consider systemic hormonal or antifibrinolytic therapy in selected HHT patients to limit ongoing gastrointestinal blood loss.</p> <p>Clinical Considerations: When unable to maintain the hemoglobin at an acceptable level, i.e., 9-10 gm/dl or higher, with oral and/or intravenous iron, then the clinician should consider hormonal therapy or antifibrinolytic therapy, in patients without contraindications. The usual dosing for hormonal therapy in HHT, based on the one study [9], is daily ethinylestradiol 0.050 mg and norethisterone 1 mg. Danacrine 200 mg orally TID for six weeks followed by 200 mg daily in responders may be a beneficial alternative in men, with less side effects. Another alternative is antifibrinolytic</p>	<p>Level of evidence: III</p> <p>Strength of recommendation: Weak</p> <p>Agreement: 100%</p>

<p>therapy, with aminocaproic acid or tranexamic acid. Aminocaproic acid is usually started at 500 mg orally QID and increased to a maximum of 2500 mg orally QID (10 gms/day). Tranexamic acid is usually started at 500 mg orally every 8-12 hours and increased to 1-1.5 grams orally every 8-12 hours. Patients should be screened and treated for PAVMs before initiating either of these systemic therapies, given the thrombogenic risk.</p>	
---	--

References

1. Ingrosso M, Sabba C, Pisani A, Principi M, Gallitelli M, Cirulli A, Francavilla A. Evidence of small-bowel involvement in hereditary hemorrhagic telangiectasia: a capsule-endoscopic study. *Endoscopy* 2004; 36(12): 1074-1079.
2. Kjeldsen AD, Vase P, Green A. [Hereditary hemorrhagic telangiectasia. A population-based study on prevalence and mortality among Danish HHT patients]. *Ugeskr Laeger* 2000; 162(25): 3597-3601.
3. Vase P, Grove O. Gastrointestinal lesions in hereditary hemorrhagic telangiectasia. *Gastroenterology* 1986; 91(5): 1079-1083.
4. Kjeldsen AD, Vase P, Green A. Hereditary haemorrhagic telangiectasia: a population-based study of prevalence and mortality in Danish patients. *J Intern Med* 1999; 245(1): 31-39.
5. Plauchu H, de Chadarevian JP, Bideau A, Robert JM. Age-related clinical profile of hereditary hemorrhagic telangiectasia in an epidemiologically recruited population. *Am J Med Genet* 1989; 32(3): 291-297.
6. Longacre AV, Gross CP, Gallitelli M, Henderson KJ, White RI, Jr., Proctor DD. Diagnosis and management of gastrointestinal bleeding in patients with hereditary hemorrhagic telangiectasia. *Am J Gastroenterol* 2003; 98(1): 59-65.
7. Proctor DD, Henderson KJ, Dziura JD, Longacre AV, White RI, Jr. Enteroscopic evaluation of the gastrointestinal tract in symptomatic patients with hereditary hemorrhagic telangiectasia. *J Clin Gastroenterol* 2005; 39(2): 115-119.
8. Proctor DD, Price J, Henderson KJ, White RI. Does the number and/or distribution of arteriovenous malformations change with age in patients with hereditary hemorrhagic telangiectasia. *Fourth International HHT Scientific Conference* 2001: 2001.
9. van Cutsem E, Rutgeerts P, Vantrappen G. Treatment of bleeding gastrointestinal vascular malformations with oestrogen-progesterone. *Lancet* 1990; 335(8695): 953-955.
10. Haq AU, Glass J, Netchvolodoff CV, Bowen LM. Hereditary hemorrhagic telangiectasia and danazol. *Ann Intern Med* 1988; 109(2): 171.
11. Korzenik JR, Topazian MD, White R. Treatment of bleeding in hereditary hemorrhagic telangiectasia with aminocaproic acid. *N Engl J Med* 1994; 331(18): 1236.
12. Bown SG, Swain CP, Storey DW, Collins C, Matthewson K, Salmon PR, Clark CG. Endoscopic laser treatment of vascular anomalies of the upper gastrointestinal tract. *Gut* 1985; 26(12): 1338-1348.
13. Sargeant IR, Loizou LA, Rampton D, Tulloch M, Bown SG. Laser ablation of upper gastrointestinal vascular ectasias: long term results. *Gut* 1993; 34(4): 470-475.
14. Gostout CJ, Bowyer BA, Ahlquist DA, Viggiano TR, Balm RK. Mucosal vascular malformations of the gastrointestinal tract: clinical observations and results of endoscopic

neodymium: yttrium-aluminum-garnet laser therapy. *Mayo Clin Proc* 1988; 63(10): 993-1003.

Liver Vascular Malformations

Background:

Though a consensus guideline had been recently published for the diagnosis and management of liver VMs in HHT[1], to be consistent, we elected to include this topic in the present guidelines. As such, we followed the same guidelines process for liver VMs as for other aspects of HHT and reviewed the evidence regarding diagnosis and treatment of liver VMs in HHT. The Liver VMs recommendations reported in the present guidelines do not differ significantly from the previous guidelines for liver VMs[1].

Liver VMs are present in 32-78% of HHT patients [2-6] (Table 6). Though there is no published natural history data regarding liver VMs in HHT, it appears that symptoms occur in only about 8% of the patients with HHT and liver VMs [4, 7]. The clinical presentations of liver VMs include high-output heart failure, portal hypertension and biliary necrosis, as detailed in a recent review[8].

In patients who have symptoms suggestive of liver VMs[8], it is important to establish the diagnosis of liver VMs for therapeutic and prognostic purposes. The diagnosis of liver VMs may also assist in the clinical diagnosis of HHT, since visceral involvement is one of the clinical diagnostic criteria [9]. Several different imaging modalities have been reported and studied for the screening and diagnosis of liver VMs in HHT. From the least invasive to the most invasive, these tests are Doppler ultrasonography (US), magnetic resonance imaging (MRI), triphasic spiral computed tomography (CT) and mesenteric angiography. Doppler US is the least invasive test, requiring no contrast and being associated with no procedural complications. There is little experience with MRI, which does require MR-contrast administration but involves no radiation exposure. CT is associated with radiation exposure and risk of contrast allergy. Mesenteric catheter angiography has traditionally been considered the diagnostic “gold standard” but is the most invasive, and is rarely used.

Typical angiographic findings have been described in several small case series of HHT patients [10-12], including telangiectasia, confluent VMs, hepatic artery dilatation and shunting (arterioportal, arteriovenous and/or portovenous). Triphasic CT findings have been similarly described [2, 3, 7]. Several case series of Doppler US in HHT patients have demonstrated hepatic artery dilatation, elevated hepatic artery flow and intrahepatic hypervascularity [3, 4, 6, 13, 14]. There have been no well-designed studies reporting sensitivity and specificity of any of these tests, though the positive predictive value of Doppler US appears to be near 100% [5, 14]. Screening studies of HHT patients (Table 6) have reported a prevalence of liver VMs of 32%-72% with Doppler US[4-6] and 67-78% with triphasic CT[2, 3]. In none of these studies was a diagnostic gold standard (angiography) uniformly performed, however, these prevalences are all much higher than the symptomatic rate (8%), suggesting that these tests are sensitive. There are no screening studies in children.

Histological diagnosis from liver biopsy tissue, although quite characteristic [8], is unnecessary, given typical imaging findings, and risky in patients with liver VMs. Focal

nodular hyperplasia (FNH) occurs more frequently in HHT than in the general population[15] but can be diagnosed through imaging, without biopsy.

There are three uncontrolled case series (Table 7) of treatments of liver VMs, specifically hepatic artery embolization and liver transplantation. Hepatic artery embolization has the objective of reducing arteriovenous or arterioportal shunting by embolizing branches of the hepatic artery. Embolization appears to be effective in improving symptoms related to high output heart failure and mesenteric steal syndrome, [16], however, the effect is transient and symptoms generally recur. More importantly, ischemic complications (ischemic cholangitis, ischemic cholecystitis and/or hepatic necrosis) leading to transplant or death occur in approximately 30% of the treated cases, including 50% of treated portal hypertension cases [16]. The 2-year survival with embolization was approximately 73%. The expert panel agreed that the risk of post-embolization ischemia would likely be greatest in patients with biliary presentation of liver VMs. With liver transplantation, symptoms resolved in the majority of patients [17, 18]. Liver transplantation is associated with high blood transfusion requirements, prolonged hospital stay and a relatively high rate of postoperative complications. However, the reported 5-year survival rate of 83% in the larger series [18] compared favorably to overall survival rates for liver transplantation.

Recommendations

<p>The expert panel recommends that in patients with HHT and abnormal liver enzymes and/or a clinical picture suggestive of complications of liver VMs:</p> <ul style="list-style-type: none"> - High output heart failure (exertional dyspnea, orthopnea, edema) - Portal hypertension (variceal hemorrhage, ascites) - Biliary (jaundice, fever, abdominal pain) - Portosystemic encephalopathy - Steal syndrome (intestinal ischemia) <p>Doppler US or CT should be offered as a baseline test to confirm liver VMs</p> <p>Clinical Considerations: The confirmation of the diagnosis of liver VMs in symptomatic patients will help prevent misdiagnosis and allow the clinician to provide appropriate therapy and follow-up. Either Doppler US or CT scan can be used to confirm the diagnosis, though Doppler US is lower risk. In centers where expertise in the interpretation of Doppler US for diagnosis of liver VMs is lacking, triphasic helical CT may be appropriate. Further, more invasive, testing may be performed depending on severity of symptoms and type of clinical presentation. For example, in patients with related heart failure, right heart catheterization with measurement of cardiac index and pulmonary pressures can</p>	<p>Level of evidence: III</p> <p>Strength of recommendation: Strong</p> <p>Agreement: 83%</p>
---	---

<p>help guide therapy and establish baseline values. In those with symptoms of heart failure versus portal hypertension, hepatic vein catheterization with measurement of hepatic venous pressure gradient can guide therapy. For patients with abdominal pain suggestive of mesenteric ischemia, angiography might clarify the diagnosis.</p>	
<p>To clarify the diagnosis of HHT, the expert panel recommends screening for liver VMs, using Doppler ultrasound, in patients with 1 or 2 HHT diagnostic criteria and in whom genetic testing is either inconclusive or unavailable</p> <p>Clinical Considerations: The rationale for recommending screening for liver VMs to clarify the diagnosis of HHT is based on the fact that visceral involvement is one of the diagnostic criteria for HHT, and therefore finding liver VMs in a patient with probable HHT can help further clarify the diagnosis of HHT. When screening is undertaken, it is advisable to screen with the least invasive test, such as Doppler US. Where expertise in Doppler US for liver VMs is lacking, a diagnosis of liver VMs can be made with triphasic CT.</p>	<p>Level of evidence: III</p> <p>Strength of recommendation: Strong</p> <p>Agreement: 78%</p>
<p>The expert panel recommends that liver biopsy be avoided in any patient with proven or suspected HHT.</p> <p>Clinical Considerations: The rationale for recommending against liver biopsy for diagnosis of liver VMs is that the diagnosis is established with imaging studies whereas biopsy exposes the patient to an unnecessary risk of hemorrhage.</p>	<p>Level of evidence: III</p> <p>Strength of recommendation: Strong</p> <p>Agreement: 97%</p>
<p>The expert panel recommends that hepatic artery embolization be avoided in patients with liver VMs as it is only a temporizing procedure associated with significant morbidity and mortality</p> <p>Clinical Considerations: Given the elevated risk of post-embolization necrosis, and death this procedure should not be considered as a first-line therapeutic option. It may be reasonable for the clinician to consider hepatic artery embolization in certain patients, such as a patient with heart failure who has failed to respond to optimal medical therapy and who does not have biliary ischemia or portovenous shunting and who is not a transplant candidate. The risks and benefits of embolization and transplant should be considered on an individualized basis, based on type of shunting, clinical syndrome, patient characteristics and patient preference.</p>	<p>Level of evidence: III</p> <p>Strength of recommendation: Strong</p> <p>Agreement: 94%</p>

<p>The expert panel recommends that referral for liver transplantation be considered in patients with liver VMs that develop:</p> <ul style="list-style-type: none"> – Ischemic biliary necrosis – Intractable heart failure – Intractable portal hypertension <p>Clinical Considerations: Since liver transplantation for liver VMs has a good survival rate, it is a reasonable option for patients with severe complications of liver VMs refractory to medical therapy. Patients who develop biliary necrosis have the highest mortality, particularly those who develop it in the setting of heart failure, and therefore should be prioritized for liver transplant, analogous to post-transplant patients that develop bile duct necrosis.</p>	<p>Level of evidence: III</p> <p>Strength of recommendation: Strong</p> <p>Agreement: 94%</p>
---	---

References

1. Buscarini E, Plauchu H, Garcia Tsao G, White RI, Jr., Sabba C, Miller F, Saurin JC, Pelage JP, Lesca G, Marion MJ, Perna A, Faughnan ME. Liver involvement in hereditary hemorrhagic telangiectasia: consensus recommendations. *Liver Int* 2006; 26(9): 1040-1046.
2. Memeo M, Stabile Ianora AA, Scardapane A, Suppressa P, Cirulli A, Sabba C, Rotondo A, Angelelli G. Hereditary haemorrhagic telangiectasia: study of hepatic vascular alterations with multi-detector row helical CT and reconstruction programs. *Radiol Med* 2005; 109(1-2): 125-138.
3. Ravard G, Soyer P, Boudiaf M, Terem C, Abitbol M, Yeh JF, Brouard R, Hamzi L, Rymer R. Hepatic involvement in hereditary hemorrhagic telangiectasia: helical computed tomography features in 24 consecutive patients. *J Comput Assist Tomogr* 2004; 28(4): 488-495.
4. Buscarini E, Danesino C, Olivieri C, Lupinacci G, De Grazia F, Reduzzi L, Blotta P, Gazzaniga P, Pagella F, Grosso M, Pongiglione G, Buscarini L, Plauchu H, Zambelli A. Doppler ultrasonographic grading of hepatic vascular malformations in hereditary hemorrhagic telangiectasia -- results of extensive screening. *Ultraschall Med* 2004; 25(5): 348-355.
5. Buscarini E, Buscarini L, Danesino C, Piantanida M, Civardi G, Quaretti P, Rossi S, Di Stasi M, Silva M. Hepatic vascular malformations in hereditary hemorrhagic telangiectasia: Doppler sonographic screening in a large family. *J Hepatol* 1997; 26(1): 111-118.
6. Ocran K, Rickes S, Heukamp I, Wermke W. Sonographic findings in hepatic involvement of hereditary haemorrhagic telangiectasia. *Ultraschall Med* 2004; 25(3): 191-194.
7. Ianora AA, Memeo M, Sabba C, Cirulli A, Rotondo A, Angelelli G. Hereditary hemorrhagic telangiectasia: multi-detector row helical CT assessment of hepatic involvement. *Radiology* 2004; 230(1): 250-259.

8. Garcia-Tsao G, Korzenik JR, Young L, Henderson KJ, Jain D, Byrd B, Pollak JS, White RI, Jr. Liver disease in patients with hereditary hemorrhagic telangiectasia. *N Engl J Med* 2000; 343(13): 931-936.
9. Shovlin CL, Guttmacher AE, Buscarini E, Faughnan ME, Hyland RH, Westermann CJ, Kjeldsen AD, Plauchu H. Diagnostic criteria for hereditary hemorrhagic telangiectasia (Rendu-Osler-Weber syndrome). *Am J Med Genet* 2000; 91(1): 66-67.
10. Hashimoto M, Tate E, Nishii T, Watarai J, Shioya T, White RI. Angiography of hepatic vascular malformations associated with hereditary hemorrhagic telangiectasia. *Cardiovasc Intervent Radiol* 2003; 26(2): 177-180.
11. Bernard G, Mion F, Henry L, Plauchu H, Paliard P. Hepatic involvement in hereditary hemorrhagic telangiectasia: clinical, radiological, and hemodynamic studies of 11 cases. *Gastroenterology* 1993; 105(2): 482-487.
12. Matsumoto S, Mori H, Yamada Y, Hayashida T, Hori Y, Kiyosue H. Intrahepatic porto-hepatic venous shunts in Rendu-Osler-Weber disease: imaging demonstration. *Eur Radiol* 2004; 14(4): 592-596.
13. Naganuma H, Ishida H, Niizawa M, Igarashi K, Shioya T, Masamune O. Hepatic involvement in Osler-Weber-Rendu disease: findings on pulsed and color Doppler sonography. *AJR Am J Roentgenol* 1995; 165(6): 1421-1425.
14. Caselitz M, Bahr MJ, Bleck JS, Chavan A, Manns MP, Wagner S, Gebel M. Sonographic criteria for the diagnosis of hepatic involvement in hereditary hemorrhagic telangiectasia (HHT). *Hepatology* 2003; 37(5): 1139-1146.
15. Buscarini E, Danesino C, Plauchu H, de Fazio C, Olivieri C, Brambilla G, Menozzi F, Reduzzi L, Blotta P, Gazzaniga P, Pagella F, Grosso M, Pongiglione G, Cappiello J, Zambelli A. High prevalence of hepatic focal nodular hyperplasia in subjects with hereditary hemorrhagic telangiectasia. *Ultrasound Med Biol* 2004; 30(9): 1089-1097.
16. Chavan A, Caselitz M, Gratz KF, Lotz J, Kirchhoff T, Piso P, Wagner S, Manns M, Galanski M. Hepatic artery embolization for treatment of patients with hereditary hemorrhagic telangiectasia and symptomatic hepatic vascular malformations. *Eur Radiol* 2004; 14(11): 2079-2085.
17. Azoulay D, Precetti S, Emile JF, Ichai P, Gillon MC, Duclos-Vallee JC, Visda S, Adam R, Castaing D, Samuel D, Bismuth H. [Liver transplantation for intrahepatic Rendu-Osler-Weber's disease: the Paul Brousse hospital experience]. *Gastroenterol Clin Biol* 2002; 26(10): 828-834.
18. Lerut J, Orlando G, Adam R, Sabba C, Pfitzmann R, Klempnauer J, Belghiti J, Pirenne J, Thevenot T, Hillert C, Brown CM, Gonze D, Karam V, Boillot O. Liver transplantation for hereditary hemorrhagic telangiectasia: Report of the European liver transplant registry. *Ann Surg* 2006; 244(6): 854-862; discussion 862-854.

Comments

The HHT Guidelines Working Group intends to generate updated clinical guidelines within approximately five years time.

Centers with recognized expertise in the diagnosis and management of HHT can be located at www.hht.org, the website for the HHT Foundation International.

The Corresponding Author has the right to grant on behalf of all authors and does grant on behalf of all authors, an exclusive licence (or non-exclusive for government employees) on a worldwide basis to the BMJ Publishing Group Ltd and its Licensees to permit this article to be published in Journal of Medical Genetics editions and any other BMJ PGL products to exploit all subsidiary rights, as set out in their licence <http://jmg.bmjournals.com/ifora/licence.pdf>.

All of the authors have contributed to the Guidelines development and the resulting manuscript. None of the authors have any significant competing interests.

Table 1. Categorization of the Quality of Evidence

Quality of Evidence	Description
I	Evidence obtained from at least 1 properly randomized, controlled trial
II-1	Evidence obtained from well-designed controlled trials without randomization
II-2	Evidence obtained from well-designed cohort or case-control analytic studies, preferably from more than 1 center or research group
II-3	Evidence obtained from comparison between times and places with or without the intervention, or dramatic results in uncontrolled experiments
III	Opinions of respected authorities, based on clinical experience, descriptive studies, or reports of expert committees

Table 2. Curaçao Criteria for clinical diagnosis of HHT.

Criteria	Description
Epistaxis	Spontaneous and recurrent
Telangiectases	Multiple, at characteristic sites: lips, oral cavity, fingers, nose
Visceral lesions	GI Telangiectasia, pulmonary, hepatic, cerebral or spinal AVMs
Family history	A first degree relative with HHT according to these criteria

Table 3. Level II study of screening tests for PAVMs in HHT patients, using reference standard.

Study	# subjects	Prevalence PAVMs	Reference Standard	Test	Sensitivity	Specificity
Cottin et al. 2004	105	45%	CT or PA	TTCE chest xray A-a gradient	93% 70% 68%	52% 98% 98%

A-a gradient=alveolar-arterial gradient calculated from arterial blood gas on room air

CT=computed tomography of the chest

PA=diagnostic pulmonary angiography

TTCE=transthoracic contrast echocardiography (using agitated saline)

Table 4. Level II uncontrolled case series of transcatheter embolization (detachable coils, balloons, etc.) for PAVMs.

Study	#subjects/ #PAVMs	Diagnosis of HHT	Mean age (years) (range)	Intervention Done	% with follow-up	Mean follow-up (months)	Outcome post- embolization	Frequency Post-emo Outcome	Procedural Complication	Frequency Complication
Pollak et al. 2006	155/415	95%	45 (7-77)	100%	100%	96	PAVM involution Reperfusion Growth small PAVMs	97% 3% 18%	Long-term Pleurisy Angina TIA	0% 12% 2% 0.5%
Prasad et al. 2004	54/306	94%	38	100%	100%	35	PAVM involution Reperfusion	93% 7%	Long-term Pleurisy Paradox embo Device misplaced PAVM perforation TIA	0% 12% <0.5% 1% 1% 1%
Mager et al. 2004	112/296	96%	45 (7-85)	100%	100%	62	Improved PaO2 pre-post Improved shunt (100% O2) pre- post Reperfusion Growth small PAVMs TIA Brain abscess	P<0.001 P<0.001 13%(patients) 8% (PAVMs) 14%(patients) 3% 2%	Pleurisy Angina Stroke TIA Paradox embo Surgical device removal Pulm HTN	13% 2% 1% 2% 2% 1% 1%

Gupta et al. 2002	66/225	83%	44 (13-77)	100%	98%	27	Improved SpO2 pre-post Improved shunt (Tc 99 MAA)	p<0.0001 p<0.0001	Long-term Pleurisy Angina Paradox embo Hemoptysis	0% 3% 5% 1% 1%
Dutton et al. 1999	53/--	79%	41 (8-70)	100%	100%	min. 3	Improved SpO2 pre-post Improved shunt (Tc 99 MAA)	p<0.0001 p<0.0001	Long-term Pleurisy Angina Confusion Stroke Paradox embo Myocardial puncture	0% 9% 3% 2% 1% 2% 1%
Lee et al. 1997	45/52 (Large PAVMs)	87%	42 (12-73)	100%	100%	56	Reperfusion	15%	Pleurisy Air embo Paradox embo	31% 2% 4%
Chilvers et al. 1990	15/--	73%	41 (13-63)	100%	100%	3	Improved SpO2 pre-post Improved shunt (100% O2) pre-post Improved peak work capacity pre-post	P<0.05 P<0.001 60%	DVT Pulm infarct	8% 8%
White et al. 1988	76/276	88%	36 (5-76)	100%	95%	min. 3	Tech success Improved O2 pre-post TIA	100% 77% 2%	Pleurisy Air embo Paradox embo DVT	10% 5% 3% 1%

Gershon et al. 2001	7/13 Pregnancy	100%	28 (24-34)	100%	100%	30	Tech success	100%	Pleurisy	29%
							Estimated fetal radiation dose	50-220 mRad	Fetal/childhood complications	0%
Faughnan et al. 2004	42/172 Pediatric	86%	12 (4-18)	100%	90%	84	Improved PaO2 pre-post	p<0.003	Long-term Pleurisy	0%
							Absence of PAVM complix (FOCAL group)	100%	Other pain	24%
							Absence of PAVM complix (DIFFUSE group)	83% (2 deaths, 1 from brain abscess, 1 from lung transplant)	Paradox embo	2%
							Reperfusion	15%	Device misplaced	1%
									Brach plex injury	0%

Brach plex=brachial plexus

Complix=complications

Embo=embolization

Paradox=paradoxical

Pulm HTN= Pulmonary hypertension

Tc99 MAA=shunt measurement using Technetium 99 labeled albumin macroaggregates

Table 5. Therapeutic trials for GI bleeding in HHT.

Study	#subjects	% HHT	Mean age (years) (range)	Intervention Done	% follow-up	Mean follow-up (mo.)	Outcome post-treatment	Frequency Post-treatment Outcome	Procedural Complication	Frequency Complication
Bown et al. 1985 Case series	18, severe GI bleeding, transfusion dependent	8/18 (44%)	62 (42-74)	100% 2 APC 6 ND-YAG (mean 7 sessions)	100%	14	Reduced transfusions No further transfusions Recurrence requiring surgery	8/8 (100%) 3/8 (38%) 3/8 (38%)	Perforation	0%
Gostout et al. 1988 Case series	93, severe GI bleeding, transfusion dependent	10/93 (11%)	63	100% ND-YAG (2-6 sessions)	100%	15	Reduced transfusions	9/10 (90%)	Perforation Delayed bleeding	3/93 (3%) 5/93 (5%)
Sargeant et al. 1993 Case series	41, severe GI bleeding, transfusion dependent	9/41 (22%)	66 (55-81)	100% ND-YAG (repeated sessions)	100%	51	Reduced or stabilized # transfusions Reduction in mean yearly transfusions pre-post	6/9 (67%) 8 (4-42) vs 4 (0-44)	Perforation Antral narrowing	1/41 (2%) 2/41 (4%)
Van Cutsem et al. 1990 Placebo-controlled crossover trial	10, severe GI bleeding from VMs, transfusion dependent	6/10 (60%)	65-89	100% ethinylestradiol+ norethisterone vs placebo	100%	6	Reduced mean transfusions pre-post* No further bleeding	p<0.002 5/6	Death (MI) Feminizing Vaginal bleeding	1/10 (10%) 1/10 (10%) 2/10 (20%)
Longacre et	43, HHT-	43/43 (100%)	57 (33-78)	23/43 (53%)	100%	18	Mean	8.6 vs 9.9	DVT	1/19 (5%)

al. 2003 Case series	related GI bleeding			medical therapy 19 ethinyl estradiol/norethi ndrone 2 danacrine 2 aminocaproic acid			hemoglobin pre-post	p=0.0018		
-------------------------	------------------------	--	--	---	--	--	------------------------	----------	--	--

*Mean for all 10 patients (HHT and non-HHT)

APC=argon plasma coagulation

Nd-YAG= neodymium-doped yttrium aluminium garnet laser

Table 6. Screening studies for Liver VMs in HHT.

Study	N	Population	%HHT	Type of study	Test	Findings for liver VMs	Frequency of abnormality in LiverVMs	Prevalence Liver VMs detected	Gold Standard
Memeo et al. 2005	105	HHT, consecutive patients	100%	Screening Descriptive	CT	Telangiectasia CVMs AV shunt AP shunt AV&APshunt Perfusion abN PHT	50/78 (64%) 20/78 (26%) 40/78 (51%) 16/78 (21%) 22/78 (28%) 46/78 (59%) 46/78 (59%)	78/100 (78%)	No
Ravard et al. 2004	24 24	HHT, consecutive patients Controls	100%	Screening Descriptive comparative	CT	Dilated HA Telangiectasia AV shunt AP shunt	16/16 (100%) 12/16 (75%) 5/16 (31%) 3/16 (19%)	16/24 (67%)	No
Buscarini et al. 2004	346	HHT, members of hht families	221 (64%)	Screening Descriptive	Doppler US	Mild Moderate Severe	11/92 (12%) 70/92 (76%) 11/92 (12%)	92/221(41%)	No
Buscarini et al. 1997	73	HHT, one family	40 (55%)	Screening Descriptive	Doppler US	Mild Moderate Severe	3/13 (23%) 3/13 (23%) 7/13 (46%)	13/40 (32%)	Angio12/13
Ocran et al. 2004	22	HHT consecutive patients	100%	Screening Descriptive	Doppler US	Dilated HA Dilated intra HA AV shunts	14/16 (88%) 15/16 (94%) 16/16 (100%)	16/22 (73%)	No

abN=abnormal ;AV=arteriovenous ; CVM=confluent vascular malformations ; HA=hepatic artery ; PHT=portal hypertension ; PV=porto-venous, VM=vascular malformations;

*4 of 6 in whom the initial diagnosis of HHT was “probable” became definite with the finding of liver VMs
clinical liver VMs= patients with clinical signs or symptoms of liver VMs

Table 7. Case series of treatment for liver VMs in HHT.

Study	N	Clinical types	Treatment	Median follow-up (months)	Outcomes of Treatment	Frequency of Outcomes	Complications	Frequency of Complications
Lerut et al. 2006	40	14 HF 12 BIL 5 PHT 6 HF+BIL 2 HF+PHT 1 HF+PHT+BIL	Trans	58	5-year survival HF improved HF Stable HF alone Death BIL+/- HF Death PHT +/- HF Death	83% 18/24 (75%) 5/24 (21%) 1/24 (4%) 4/18 (22%) 3/8 (38%)	Intraoper bleed [†] GI bleed [†] CHF [†] Acute rejection [†] Chronic rejection [†] Graft failure [†] Cerebral bleed [†] PAVM bleed [†] Non-fatal complications	1/40 (3%) 1/40 (3%) 1/40 (3%) 1/40 (3%) 1/40 (3%) 1/40 (3%) 1/40 (3%) 1/40 (3%) 24/40 (60%)
Chavan et al. 2004	15	11 HF 5 Steal 4 PHT	Staged HA embo	28	Alive HF alive HF improved Steal alive Steal improved PHT alive PHT improved	11/15(73%) 10/11 (91%) 10/11 (91%) 5/5 (100%) 5/5 (100%) 2/4 (50%) 2/4 (50%)	Hepatic necrosis [†] Cholangitis/ cholecystitis [†]	1/15 (7%) 3/15 (20%)
Azoulay et al. 2002	6	3 BIL 2 PHT 1 HF+ BIL	Transplant	57	Alive BIL alive PHT alive HF+BIL alive	4/6 (67%) 3/3 (100%) 1/2 (50%) 0/1 (0%)	GI bleeding [†] Peritonitis [†]	1/6 (17%) 1/6 (17%)

HA= hepatic artery, HF=high output heart failure; PHT= portal hypertension; BIL=biliary

[†]Causing death

Acknowledgements

Many thanks to the following people who contributed at different stages to the HHT Guidelines: Marianne Clancy MPA, Justine Cohen-Silver MD MSc, Sharon Straus MD MSc, Dave Davis MD, Mary Ellyn Parker RN, Ana Carvalho, Joyce Fenuta RN BScN MHS, Beth Plahn RN MHA, David Stoner BS RPh, Keith Williams, Cheryl Wilson MA MS, Jane E. Tumpson MAT MBA, Samir Gupta MD MSc, Kevin Sanders MD MSc, Anna R. Gagliardi PhD, Andrew Worster MD and Denice Feig MD MSc.

Funding

Funding Sources: John Abele on behalf of the Argosy Foundation, HHT Foundation International Inc., Canadian Institutes of Health Research, St Michael's Hospital Department of Medicine

Financial support (M.E.F.): Nelson Arthur Hyland Foundation, Li Ka Shing Knowledge Institute of St. Michael's Hospital

Appendix I. Background Literature Review

We utilized the database OVID medline and searched for articles between the dates of 1966 to present. We used related MESH headings, then exploded search, and also included all related terms/spellings as “keywords”.

Topic	MESH and Key Words	Inclusion Criteria for Diagnostic Evidence Table	Inclusion Criteria for Treatment Evidence Table
HHT Diagnosis	Telangiectasia, hereditary hemorrhagic Rendu-Osler-Weber HHT Arteriovenous malformations AND Mutation <i>SMAD4</i> Endoglin, <i>ENG</i> Activin Receptor, type I <i>ALK1</i> <i>ACVRL1</i> HHT1 HHT2	English language Human studies N>5 Articles required the following information: 1) Results including sensitivity and specificity of diagnostic tests OR 2) Raw data which would allow for calculation of sensitivity and specificity of diagnostic tests.	Not applicable
Epistaxis	Telangiectasia, hereditary hemorrhagic Rendu-Osler-Weber HHT AND Epistaxis Nosebleed Laser Cryotherapy Septal dermoplasty Young’s procedure Embolization Cautery or electrocoagulation Hormones or hormone therapy Aminocapric acid Tranexamic acid	English language Human studies N>5 Articles required the following information: 1) Results including sensitivity and specificity of diagnostic tests OR 2) Raw data which would allow for calculation of sensitivity and specificity of diagnostic tests.	English language Human studies N>5 Exclusion: Review articles or Comment articles without raw data No treatment outcomes reported Study patients not sufficiently described

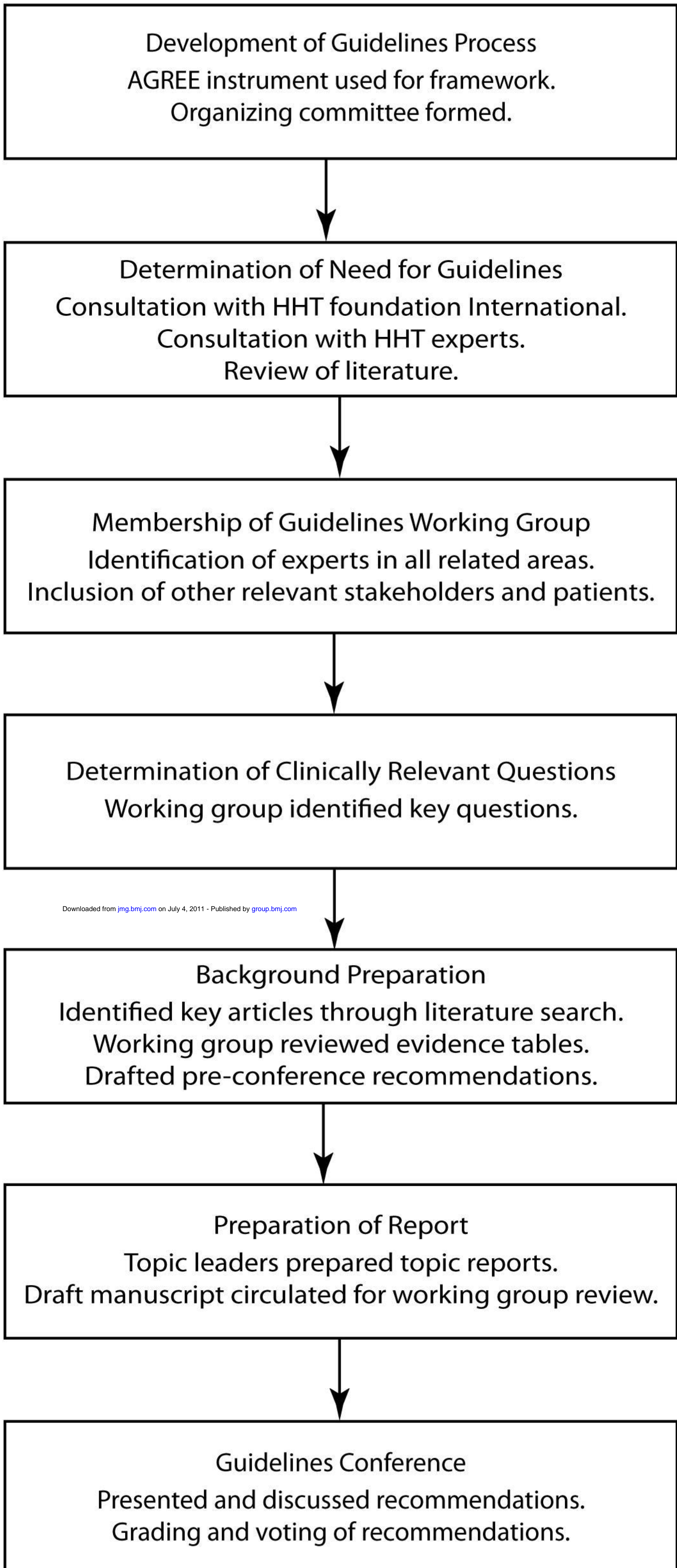
CVMs	Arteriovenous malformation CAVM Cerebral arteriovenous malformation Brain arteriovenous malformation Intracranial arteriovenous malformations/ or exp central nervous system vascular malformations AND Sensitivity and specificity Randomized Controlled Trials Case-Control Studies Clinical Trails	English language Human studies N>5 Articles required the following information: 1) Results including sensitivity and specificity of diagnostic tests OR 2) Raw data which would allow for calculation of sensitivity and specificity of diagnostic tests.	English language Human studies N>200 Exclusion: Review articles or Comment articles without raw data No treatment outcomes reported Study patients not sufficiently described
PAVMs	Telangiectasia, hereditary hemorrhagic Rendu-Osler-Weber HHT AND Pulmonary arteriovenous malformation Lung arteriovenous malformation PAVM	English language Human studies N>5 Articles required the following information: 1) Results including sensitivity and specificity of diagnostic tests OR 2) Raw data which would allow for calculation of sensitivity and specificity of diagnostic tests.	English language Human studies N>5 Exclusion: Review articles or Comment articles without raw data No treatment outcomes reported Study patients not sufficiently described
GI Bleeding	Telangiectasia, hereditary hemorrhagic Rendu-Osler-Weber HHT AND Gastrointestinal arteriovenous malformation Gastrointestinal tract/intestinal/ lower gastrointestinal tract	English language Human studies N>5 Articles required the following information: 1) Results including sensitivity and specificity of diagnostic tests OR 2) Raw data which would allow for calculation of sensitivity and specificity of diagnostic tests.	English language Human studies N>5 Exclusion: Review articles or Comment articles without raw data No treatment outcomes reported Study patients not sufficiently described
LVMs	Telangiectasia, hereditary hemorrhagic Rendu-Osler-Weber HHT AND	English language Human studies N>5 Articles required the following information:	English language Human studies N>5

	<p>Liver arteriovenous malformation Hepatic arteriovenous malformation Liver/bile ducts, intrahepatic/intrahepatic/hepatic</p>	<ol style="list-style-type: none"> 1) Results including sensitivity and specificity of diagnostic tests OR 2) Raw data which would allow for calculation of sensitivity and specificity of diagnostic tests 	<p>Exclusion: Review articles or Comment articles without raw data No treatment outcomes reported Study patients not sufficiently described</p>
--	---	---	---

Appendix II. Future research priorities for HHT in general and each Topic.

Topic	Future Research Priorities
General	<ul style="list-style-type: none"> • Improve quality of evidence in all areas of diagnosis and treatment of HHT • Better define natural history of HHT by developing multicenter collaborative database • Study implementation and knowledge translation of practice guidelines in rare disease • Revise guidelines regularly, as diagnostic technology improves, new treatments become available and evidence improves • Further develop and validate Quality of Life instruments in HHT, and include these as study outcomes
Diagnosis	<ul style="list-style-type: none"> • Determine sensitivity and specificity of Curacao Criteria in different age groups • Better identify natural history of HHT • Further identify prevalence of SMAD4 mutation in HHT and phenotype with SMAD4 mutation • Identify the two additional suspected HHT genes • Study uptake of recommendations for children • Assess quality of life impact of early HHT diagnosis
Epistaxis	<ul style="list-style-type: none"> • Develop and validate a patient-based outcome instrument, which incorporates both subjective (i.e., physical symptoms, functional limitations, and emotional/social limitations) and objective (i.e., severity of anemia, need for transfusion) parameters, for measurement of epistaxis (high priority) • Develop and study novel therapies for telangiectasia, for example, antiangiogenic therapy, etc.
CVMs	<ul style="list-style-type: none"> • Better define natural history of CVMs in HHT, through multicenter collaborative database • Define morphology of CVMs in HHT and relationship to clinical outcomes, through multicenter collaborative data collection • Study treatment options for CVMs in HHT, through multicenter collaborative research
PAVMs	<ul style="list-style-type: none"> • Determine accuracy and safety for screening tests for PAVMs in children • Study outcomes of long-term re-screening for PAVMs in order to establish appropriate screening interval • Determine natural history of patients with suspected microscopic PAVMs (positive TTCE but no PAVMs detectable on CT) • Study use of other contrast agents, for TTCE, than agitated saline • Collect better safety data about TTCE in this population
GI Bleeding	<ul style="list-style-type: none"> • Evaluate and compare traditional and novel therapies for GI bleeding in HHT in multicenter collaborative studies
Liver VMs	<ul style="list-style-type: none"> • Determine appropriate timing and indications for liver transplantation • Development and study of novel therapies for liver VMs, for example, antiangiogenic therapy, etc.

Figure. The adopted process of guideline development





International Guidelines for the Diagnosis and Management of Hereditary Hemorrhagic Telangiectasia

M E Faughnan, V A Palda, G Garcia-Tsao, et al.

J Med Genet published online June 23, 2009
doi: 10.1136/jmg.2009.069013

Updated information and services can be found at:
<http://jmg.bmj.com/content/early/2009/06/29/jmg.2009.069013>

	<i>These include:</i>
References	Article cited in: http://jmg.bmj.com/content/early/2009/06/29/jmg.2009.069013#related-urls
P<P	Published online June 23, 2009 in advance of the print journal.
Email alerting service	Receive free email alerts when new articles cite this article. Sign up in the box at the top right corner of the online article.

Notes

Advance online articles have been peer reviewed and accepted for publication but have not yet appeared in the paper journal (edited, typeset versions may be posted when available prior to final publication). Advance online articles are citable and establish publication priority; they are indexed by PubMed from initial publication. Citations to Advance online articles must include the digital object identifier (DOIs) and date of initial publication.

To request permissions go to:
<http://group.bmj.com/group/rights-licensing/permissions>

To order reprints go to:
<http://journals.bmj.com/cgi/reprintform>

To subscribe to BMJ go to:
<http://group.bmj.com/subscribe/>